

**ANTHOCYANINS: A HUE FOR HISTOLOGY - SYSTEMATIC REVIEW**Shiny Jasphin<sup>1a</sup>, Archana Parampalli Raghavendra<sup>2a\*</sup>, Monica Charlotte Solomon<sup>3b</sup>, Arul Amuthan<sup>4c,d</sup>, Brij Mohan Kumar Singh<sup>5e</sup>, Nikitha Valerina Kairanna<sup>6e</sup>

**Abstract:** Background: Many histological stains cause health hazards to technicians, pathologists, and researchers. The hazard-free and eco-friendly natural anthocyanins have the potential to be a new source for histological stains. This study aims to systematically review the use of plant products containing anthocyanin for histopathological diagnosis. Methods: A comprehensive literature search was done using suitable keywords on Wiley, PubMed, Scopus, Google Scholar, and Web of Science databases. A total of 30 articles were selected for systematic review, where data obtained from the studies were tabulated. Results: About 90% of the reviewed studies have proven that anthocyanin-containing plant products may be used as natural stains. Out of the 30 studies, 49% involved the use of Hibiscus extract, 11% utilised mulberry extract, 9% utilised pomegranate, another 9% involved rose, and the remaining ones utilised black plum, black rice, butterfly pea, the flame of woods, onion skin, and red poppy extracts. Almost 40% of the studies concluded that aqueous extracts are superior to alcohol ones, and 46% used either iron or alum as mordant. Conclusion: Natural stains containing anthocyanin could be a better alternative to synthetic histological stains. Further extensive studies should be conducted to observe the use of these stains in pathological diagnosis.

**Keywords:** Anthocyanin, histology, natural dyes, natural stains

**1. Introduction**

Histopathology is the study of biological tissues to detect diseased cells using a microscope – a major diagnostic tool in preclinical and clinical conditions research. Various processes like fixation, dehydration, clearing, embedding, sectioning, and staining are involved in converting tissue into stained sections (Ramamoorthy et al., 2016). Because of the transparent nature of the tissue samples, the cellular and intercellular structures are not visible microscopically. Therefore, they are coloured using dyes during the staining process. Usually, the histopathological diagnosis of any

disease involves the examination of slides stained with the following three stains: Haematoxylin & Eosin (H&E) (the routine stain used in laboratories), special stains (stains specific cells, tissues, structures, microorganisms, etc.), and immunohistochemistry (stains specific proteins). The staining process involves various chemicals that may cause health hazards to pathologists, technicians, researchers, and the environment. Hence, there is a necessity to discover and develop new natural stains for histopathological diagnoses.

**1.1 Stains used for histopathological diagnoses****1.1.1 Haematoxylin & Eosin**

H&E is the most commonly used stain for identifying the nucleus and cytoplasm in cells. Haematoxylin is a natural dye obtained from the Mexican logwood tree, *Haematoxylum campechianum* (Ajilleye et al., 2015). Haematoxylin has a good affinity to the myelin sheath, nuclei, collagen, and elastic fibres. Easy differentiation, durability, and comparative permanency are haematoxylin's advantages, making it a popular stain for the nucleus. There is a worldwide shortage of haematoxylin, so its cost has steadily increased (Dapson et al., 2010; Mohandas et al., 2019).

On the other hand, Eosin is a synthetic acidic xanthene dye formed through the reaction between fluorescein and bromine (Mohandas et al., 2019). It is used as a counterstain that colours the essential components of tissues in shades of red and pink (Lahiani et al., 2018). The International Agency

**Authors information:**

<sup>a</sup>Dept of Physiology, Melaka Manipal Medical College (Manipal Campus), Manipal Academy of Higher Education, Manipal, Karnataka, INDIA-576104. Email: shiny.jasphin@learner.manipal.edu<sup>1</sup>; archana.h@manipal.edu<sup>2</sup>

<sup>b</sup>Dept of Oral Pathology, Manipal College of Dental Sciences, Manipal, Manipal Academy of Higher Education, Manipal, Karnataka, INDIA-576104. Email: monica.charlotte@manipal.edu<sup>3</sup>

<sup>c</sup>Dept of Pharmacology, Melaka Manipal Medical College, (Manipal Campus), Manipal Academy of Higher Education, Manipal, Karnataka, INDIA-576104. Email: dramathanmd@gmail.com<sup>4</sup>

<sup>d</sup>Division of Siddha, Center for Integrative Medicine and Research, Manipal Academy of Higher Education, Manipal, Karnataka, INDIA-576104. E-mail: dramathanmd@gmail.com<sup>4</sup>

<sup>e</sup>Dept. of Pathology, Kasturba Medical College, Manipal, Manipal Academy of Higher Education, Manipal, Karnataka, INDIA-576104. Email: brij.singh@manipal.edu<sup>5</sup>; nikita.kairanna@manipal.edu<sup>6</sup>

\*Corresponding Author: archana.h@manipal.edu

Received: November 2, 2021

Accepted: September 5, 2022

Published: February 28, 2023

of Research in Cancer has considered Eosin as a group 3 carcinogen (Anonymous, 2020). Even though this synthetic dye works well as a staining agent, it is hazardous to humans and animals (Mohandas et al., 2019).

### 1.1.2 Special stains

Special stains are an alternative staining technique to H&E used when the latter does not highlight adequate information required by pathologists and researchers. The use of special stains utilises various techniques and dyes that stain specific structures, tissues, or pathogens that help pathologists with their diagnosis (Bordoloi et al., 2017). The stains used for colouring sperm structures and their viabilities are Eosin & Nigrosin, Giemsa, Diff Quick, and silver nitrate. These are non-biodegradable synthetic substances hazardous to water sources and the environment (Ebrahimi & Parham, 2020). Besides that, Giemsa and Diff-Quick stains are used for staining cytological smears (Suebkhampet & Sotthibandhu, 2012). On the other hand, peripheral blood smears are stained with Romanowsky stains like Giemsa and Leishman's. The composition of these stains includes Eosin B or Eosin Y – which are acidic – and methylene blue – which is basic (Cruz et al., 2018). Giemsa stains are also used for staining parasites like Plasmodium, Microflaria, Leishmania donovani, Entamoeba histolytica, and others (Kamal, 2018). Common microbial stains used in laboratories are Acid Fast and Gram stains for bacteria and Lactophenol and Gomori's methamine silver stains for fungi (Ma'aruf et al., 2020). The crystal violet in Gram staining is a possible carcinogen and is harmful to aquatic animals (Bordoloi et al., 2017). Most synthetic dyes are allergenic, carcinogenic, mutagenic, immunogenic, challenging to prepare, and expensive. They can damage the environment and reduce soil fertility (Bondoc, 2018). Frequent and constant Exposure to these chemicals has led to health hazards for laboratory technicians, pathologists, and researchers (Sudhakaran et al., 2018).

## 1.2 Natural dyes

The increasing awareness of the hazards of synthetic dyes has led to the use of eco-friendly, non-allergic, non-toxic dyes in textiles (Verma & Gupta, 2017). Natural dyes derived from natural resources like plants, microbes, animals, and minerals are called natural dyes. The most common source of natural dye are plants (Singh, 2017; Siva, 2007). Natural dyes have no allergenic or carcinogenic effects on human beings. They are biodegradable, renewable, and readily available. Natural dyes are used widely in industries like cosmetics, leather, textiles, food products, paint, etc. (Verma & Gupta, 2017).

Plants produce many colourful phytochemicals in stems, roots, leaves, fruits, and flowers which can be used as dyes (Akinloye & Olagoke, 2010; Siva, 2007). These dyes consist of compounds like anthraquinones, flavones, dihydropyrans,

anthocyanins, carotenoids, and others (Vankar, 2000). Nowadays, natural dyes are also used to stain histological tissue specimens. Most natural dyes require chemicals called mordants that help to fix and intensify the stains to tissues and cells during the staining preparations. Together with the dyes, mordants form a coordination complex called 'lake', which is then attached to the tissues. Because of this property, mordants are regularly used in staining protocols (Suebkhampet & Sotthibandhu, 2012). The complex formed is mostly positively charged and acts as a cationic dye at low pH values. The most common mordants used in staining protocols are salts of iron, chromium, aluminium, and others (Veuthey et al., 2014).

Natural dyes are classified based on their source, chemical structure, colour, etc. The most important classification is based on their chemical structures, where they are categorized into indigoid dyes, anthraquinone dyes, carotenoids, anthocyanins, etc. (Siva, 2007; Vankar, 2000).

### 1.2.1 Anthocyanins

The term 'Anthocyanins' is derived from two Greek words – Anthos (flower) and kianos (blue) (Castañeda et al., 2009). Anthocyanin accounts for a large group of plant pigments that give attractive colours to fruits, flowers, and grains (Hou et al., 2013). Anthocyanins are water-soluble coloured pigments that belong to the phenol group (Khoo et al., 2017). These pigments are presented in the form of heterosides. Anthocyanins contain a flavonoid molecule that is synthesised by the phenylpropanoid pathway (Shaik et al., 2018).

The basic structure of anthocyanin is anthocyanidin. The structure of anthocyanidin consists of an aromatic ring that is bonded to a heterocyclic ring. The heterocyclic ring consists of an oxygen atom which is bonded by a carbon-carbon bond to another aromatic ring (Fig 1).

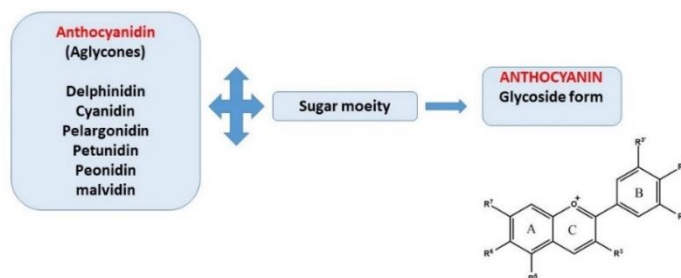


Figure 1. The basic structure of anthocyanin

The common types of anthocyanidins are delphinidin, cyanidin, pelargonidin, petunidin, peonidin, and malvidin. Anthocyanidins (aglycone) are called anthocyanin when they are attached to a sugar moiety (glycoside form) (Castañeda et al., 2009; Khoo et al., 2017; Zulfajri & Muttakin, 2018). The 7-hydroxy flavylum ion is the basic chromophore of anthocyanins. The colours of anthocyanins range from yellow to purple and depend on many factors like pH, substituents in the B-ring, aggregations of anthocyanin, complexation by organic molecules and metal ions, and others (Quina et al., 2009).

Besides that, most anthocyanins act as pH indicators (Zulfajri & Muttakin, 2018). They are soluble in many polar solvents like ethanol, acidified methanol, and water due to their polar nature. The extraction of anthocyanins is usually done with methanol. An acid is added to lower the pH, which prevents the degradation of non-acylated anthocyanin colourants. The extraction of anthocyanin from plant products is influenced by many factors including solvent used, temperature, and time is taken for the extraction (Mat Nor & Arof, 2016). In plants, the anthocyanin level is less during high-temperature conditions, which might be due to reduced synthesis or increased degradation (Charurungsipong et al., 2020; Dela et al., 2003). Anthocyanins' stability is very low and may be destroyed due to many factors like light, pH, enzymes, oxygen, thermal treatment, ascorbic acid, co-pigments, and metal ions (Castañeda et al., 2009; Hou et al., 2013). Furthermore, Anthocyanin pigments are more stable in acidic conditions with red colour. It produces a pH-dependent colour that changes from red to yellow, purple, violet and blue in alkaline conditions. At low pH, the molecule is protonated (cation or positive ion). It becomes deprotonated (anion, negative ion) as its pH is gradually increased. Therefore, the ideal working pH to retain the original anthocyanins' colour is below 4 (Khoo et al., 2017; Wahyuningsih et al., 2017).

Many nuclear stains used in histology contain phenolic compounds. The cationic nature of anthocyanins and their planar structure allow them to interact with nuclear DNAs by intercalation. As there are cations in the chemical structure of anthocyanins, they easily interact with the

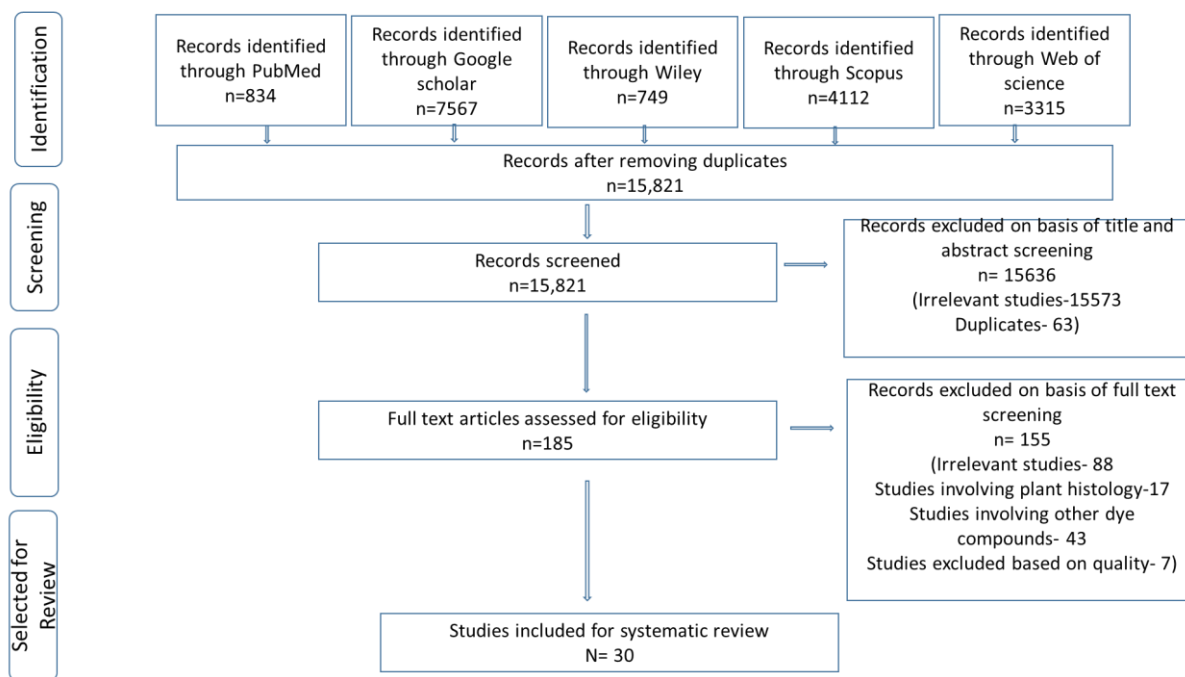
polynucleotides of the nucleus (Suebkhampet & Sotthibandhu, 2012).

Numerous studies have explored the staining effects of natural dyes on histopathological diagnoses. Different plant products containing anthocyanins are also used to stain histological tissues, cytological smears, and micro-organisms. Leveraging the vast literature on this topic, this study aims to systematically review the use of anthocyanin-based natural stains from plant products like *Morus nigra* (black mulberry), *Oryza sativa* (black rice), *Clitoria ternatea* L. (butterfly pea), *Allium cepa* (onion skin), *Syzygium cumini* (black plum), *Punica granatum* (pomegranate), *Ixora coccinea* L. (santan flower), *Hibiscus sabdariffa* (rosella), *Rosa damascena* (damask rose), and *Papaver rhoeas* (common poppy) for histopathology. This review is more concerned with exploring the methodology involved in processing the stains, including elements like the extraction methods, the use of mordants, the pH value maintained, and staining time.

## 2. Methodology

### 2.1. Systematic review

The researchers carried out a comprehensive literature search from Wiley, PubMed, Scopus, Google Scholar, and the Web of Science databases. Keywords like anthocyanin, organic stains, natural dyes, dye extract, and individual plants containing anthocyanins like hibiscus, berry, and others (with their botanical names) were used in combination with words like histology and staining. Studies that have used anthocyanin-based plant parts for staining animal and human tissues, blood smears, sperm, bacteria, fungus, and parasites are selected for the review. Studies involving the staining of plant tissues were excluded from this review. The researchers have also selected 30 articles from different databases showing the staining properties of ten different plant products containing anthocyanin in animal and human tissues, blood smears, sperm, bacteria, fungus, and parasites (Flowchart 1). The basic structure of anthocyanin is anthocyanidin. The structure of anthocyanidin consists of an aromatic ring that is bonded to a heterocyclic ring. The heterocyclic ring consists of an oxygen atom which is bonded by a carbon-carbon bond to another aromatic ring (Fig 1).



Flowchart 1. Prisma flowchart of this review

### 3. Results and Discussions

Upon obtaining the final set of studies, a systematic review was carried out, and data obtained from the review was tabulated. A meta-analysis could not be performed due to the heterogeneity of the reviewed studies.

#### 3 RESULTS

##### 3.1 Systematic review

The researchers reviewed 30 studies that utilized ten plant products producing anthocyanin. Out of the 30 articles, three reported comparative staining properties of more than

one plant product, while the remaining reported staining properties of single plant products. In 49% of the studies, staining was done with Hibiscus sabdariffa and Hibiscus rosa-sinensis; 11% of them used Morus nigra and Morus alba, 9% used Punica granatum, another 9% used Rosa damascene, while the remaining ones involve other plants. About 45% of the study was carried out on histological tissues, while the remaining were on cell smears, sperm, parasites, and fungi. Nearly 91% of the studies proved that anthocyanin-containing plant products could be used for staining. Data obtained from the studies are outlined in Table 1.

Table 1. Total fecal samples collected and parasites identified

No.	Dye source, extract, staining solution (SS), staining time (ST), tissues	Observation/Result	Inference, Reference
1	Morus nigra Extract - aqueous (50 g/200 ml) ST - 30-60 min Tissue - rat brain	Neurons: Cortex-dark brown Hippocampus-dark brown Thalamus-light brown Hypothalamus-light brown  Astrocytes: Cortex-strong staining Hippocampus-strong staining Thalamus-faint staining Hypothalamus-faint staining	Identification of different parts of the brain is possible.  Comparison between astrocytes and neurons is possible (E. M. Tousson & Al-Behbehani, 2010).

No.	Dye source, extract, staining solution (SS), staining time (ST), tissues	Observation/Result	Inference, Reference
2	Morus nigra Extract-aqueous (50 g/200 ml) ST - 5-10 min, Tissue - adult liver flukes (Fasciola sp)	All parts of a liver fluke like the oral and ventral sucker, pharynx, and intestine, are stained.  Reproductive organs are more easily identified by blackberry dyes compared with carmine staining.	Black mulberry has many advantages over conventional staining. (E. Tousson & Al-Behbehani, 2011).
3	Morus nigra Extract- aqueous (50 g/100 ml) SS -1 g of extract + 2 ml of distilled water (DW) Tissue - bull semen	Black mulberry stained red in colour with pale pink background	Control slides stained with eosin/nigrosine could differentiate between live and dead sperm cells, but blackberry could not differentiate (Ebrahimi & Parham, 2020).
4	Oryza Sativa, Clitoria ternatea, Hibiscus sabdariffa, Morus alba Extract - aqueous SS- 100 g extract + 100 ml of solvent A, B, C. A=5 ml ethanol+10 ml alum+4 ml acetic acid+100 ml DW. B=5 ml ethanol+ 4 ml acetic acid+ 100 ml DW. C=5 ml ethanol+10 ml alum+ 100 ml DW. ST-15 min. Tissue - sperm	Slides stained with black rice and mulberry extracted with Solvent C showed clear morphology of acrosome, middle piece and tail.	Potash alum is an essential component of black rice dye staining.  Black rice extract can be a cheap alternative to standard PAP stain for spermatozoa assessment. (Chomean et al., 2019).
5	Oryza sativa Extract - aqueous SS- Sperm in clothing (100 g in 10 g of potassium alum in 100 ml distilled water), Vaginal swab-100 g in 10 g of potassium alum +100 ml distilled water+4, ml of ethanol+5 ml of acetic acid). ST-1,3,5, and 7 mins Tissue- spermatozoa in vaginal swab and clothing sample	The staining time of 5, 7, and 9 mins stained well with sperm morphology comparable to reference stain (Dip quick stain)	Oryza sativa extract can be used as an alternative to haematoxylin for detecting spermatozoa on vaginal swabs and clothing (Saenguthai et al., 2018).
6	Clitoria ternatea L. Extract - aqueous (1:10) SS- extract +1% aluminium chloride +1.2% Iron III chloride, Ph-0.2. ST-30 mins Tissue- blood smear of chicken, pigeon, dog, and horse	The cytoplasm of RBC of all species - is greyish pink. Nuclei of RBC of pigeons and chickens were stained more intensely than WBC. Different types of WBC showed different nuclei shapes and specific cytoplasmic granules.	Aqueous extract of Clitoria ternatea L. could be used to differentiate blood cells of animal smears compared with a Diff-quick stain. (Suebkhampet & Sotthibandhu, 2012).
7	Allium cepa Extract-Aqueous (20 g in 100 ml) SS- extract without mordant, extract + alum, extract + FeSO <sub>4</sub> , extract + CuSO <sub>4</sub> ST-1 hr at 25°, 50°, and 80° Tissue- buccal epithelial cells	The best cytoplasm staining condition was seen when stained for 1 hr at 50° and 80° without mordant. Best nucleus staining was seen with mordants FeSO <sub>4</sub> and CuSO <sub>4</sub> at 25°, 50°, and 80°	Onion skin can be used for replacing histological staining. (Kusculuo et al., 2017).
8	Syzygium cumini Extract- aqueous- fresh material (1:2) and dried material (1:5)	All prepared stains stained the nucleus and cytoplasm in violet colour. The intensity of staining	Black plum can be used as an alternative for histological staining. (Suabjakyong et al., 2011).

No.	Dye source, extract, staining solution (SS), staining time (ST), tissues	Observation/Result	Inference, Reference
	SS - fresh- 45% glacial acetic acid (1:5) and dried- 45% glacial acetic acid (1:10). Both were with and without 1% ferric alum. ST-10, 15, and 20 min. Tissue - rat liver	done for 15 to 20 mins was more than 10 mins.	
9	Punica granulatam Extract-aqueous (20 g in 100 ml) SS- no alum and 2 g alum ST-1 hr at 100° in oven Tissue - human blood cells	Blood cells like neutrophils and basophils showed orange-brown colour with the nuclei deep orange to the brown colour in all groups.	Pomegranate is an environment-friendly, natural stain for human blood cells. (Kuskuluo & Benli, 2017).
10	Punica granulatam Extract-aqueous (20 g in 100 ml) ST-1 hr at 60° in the oven. Tissue - rat lung, liver, heart, kidney	Weak staining of both cytoplasm and nuclei was seen in all tissues, with more intensity staining in heart tissue.	Darker stain can be obtained by changing temperature and pH, increasing staining time, and adding mordant. (Kusculu & Aslan, 2019).
11	Punica granulatam Extract- ethanol (20 g in 100 ml) SS- different pH 1-2, 4-5 ST- Room temperature for 1 hr, 100° for 1 hr. Tissue - rat ovary, testis	At pH 1-2: Tissues stained purple. At pH 4-5: Tissues stained green-yellow. At 100° - brown. At room temperature- light green	Pomegranate stain can be used for staining testicular tissue for histopathological diagnosis. (Kuskuluo, 2018).
12	Ixora coccinea L Extract - ethanol 25% (33.85 g/ 101.5 ml) and 36%-(33.85/ 60.18 ml) Tissue - blood smear	The smears were poorly stained.	25% stain is more potent for staining WBC than 36% concentration. However, Ixora coccinea is not effective staining for WBC due to poor quality, poor and unclear demonstration of cell morphologies (Cruz et al., 2018).
13	Hibiscus sabdariffa, Rosa damascene Extract- aqueous (10 g /100 ml), 96% ethanol (50 g/100 ml) Rosa-96% ethanol (50 g/100 ml) ST-30 mins Tissue- Leishmania donovani	Hibiscus Water-Pinkish colour Alcohol- Bluish pink colour Rosa Alcohol-Pink red	Water extract and alcoholic extract of Hibiscus sabdariffa followed by Rosa damascene have the potential to replace the standard stain used for staining Leishmania parasite. (Kamal, 2018)
14	Hibiscuss sabdariffa, Rosa hybrida Extract-aqueous (50 g/100 ml), 96% ethanol (50 g/100 ml) ST-1-2 days Tissue - Fasciola gigantica, Gastrothylax crumenifer, Platyhelminthes, Taenia solium, and Moniezia expansa	Water and alcoholic extracts of Rosa hybrida stained all parts, including the internal organs of the parasites, compared with the hibiscus. Aqueous extracts of both flowers gave good contrasts compared with alcoholic extracts.	Rosa hybrida, followed by Hibiscus sabdariffa, has the potential to replace standard stains used to stain helminth parasites. (Kumar et al., 2015).
15	Rosa damascene- 95% ethanol (maceration-15 g/500 ml, Soxhlet- 500 g/500 ml) SS- no mordant and with 10 g of potassium alum, pH-6.2 ST-20 mins Tissue-normal oral mucosa and pathological oral tissues	Soxhlet apparatus extraction is better than maceration. The staining with mordant showed better staining than extract without mordant. Rose extract showed comparable results with H & E.	Rosa damascene extracted with advanced technique and appropriate mordant can give staining comparable with H & E. (Surendra et al., 2018).



No.	Dye source, extract, staining solution (SS), staining time (ST), tissues	Observation/Result	Inference, Reference
16	Papaver rhoeas Extract- aqueous (40 g/100 ml), ethanol (30 g/100 ml) SS- extract + acetified ethylene glycol+ NaIO <sub>3</sub> + AlCl <sub>3</sub> + beta cyclo dextrin. ST-5 min. Tissue - rat lung and intestine	The nucleus was prominent and well-defined dark purple in all cells.	Papaver rhoeas can be an alternative to haematoxylin, which is cheap, convenient, and renewable. (Budak & Budak, 2015).
17	Hibiscus sabdariffa Extract- aqueous (25 g/125 ml), alcohol (25 g/125 ml) SS- extract +3 g potassium alum. Tissue- fungi like Aspergillus nidulans, Rhizoctonia, Rhizopus stolonifera, P. citrinum, and Cladosporium species	Both extracts have a good affinity towards fungal sporangia, mycelia, and all external features. The aqueous extract was a little superior to the alcoholic extract.	The staining obtained was similar to the standard dyes. A cheaper and eco-friendly dye from Hibiscus sabdariffa calyx can be used for fungal staining (Abubakar et al., 2012).
18	Hibiscus sabdariffa Extract- aqueous (10 g/200 ml) SS- extract + NaCl 5 g + 10% FeCl <sub>3</sub> + Glacial acetic acid-3 ml. Tissue- cerebellum, cerebrum, pons	The nucleus of the brain tissues stained dark violet, comparable with the H&E control	Hibiscus sabdariffa can be used as a nuclear substitute for staining brain tissues ( Benard et al., 2015)
19	Hibiscus sabdariffa Extract- aqueous (10 g/200 ml) SS- extract + NaCl 5 g + 10% FeCl <sub>3</sub> + glacial acetic acid-3 ml ST-5 min. Tissue – skin	Nucleus staining was seen in blue-black colour.	Hibiscus sabdariffa can be used as a progressive nuclear stain to demonstrate connective tissue of the skin (S. Benard, Afolabi, et al., 2017).
20	Hibiscus sabdariffa Extract- aqueous (10 g/200 ml) SS- extract + NaCl 5 g + 10% FeCl <sub>3</sub> + glacial acetic acid-3 ml ST-20 min. Tissue - lymph node and appendix tissue	Nuclei stained dark violet-blue.	Hibiscus sabdariffa can be used as an alternative to haematoxylin (Solomon A. Benard, 2008).
21	Hibiscus sabdariffa Extract- aqueous (10 g /200 ml) SS- extract + NaCl 5 gm + 10% FeCl <sub>3</sub> + Glacial acetic acid-3 ml SS-5 min Tissue - human skin	Hibiscus gave good staining of skin morphology and collagen fibres.	Histomorphological features of the skin, collagen, and nucleus can be well demonstrated with the hibiscus Van Gieson method. ( Benard, Muhammed, et al., 2017).
22	Hibiscus sabdariffa Extract- aqueous (10 g /100 ml) SS-100 ml of hibiscus solution + 10 ml of saturated picric acid ST-30 min Tissue - biopsy from patients of muscular dystrophy, cardiac myo infarction, skeletal muscle specimen from MDX mice	Normal muscle and red blood cells stained yellow, and degenerated muscle fibres stained dull pink.	Picro-hibiscus staining helps to differentiate viable muscle fibres from necrotic muscle fibres and normal from degenerated muscle fibres. (Gowali, 1995).
23	Hibiscus sabdariffa Extract- aqueous (10 g /200 ml) SS- extract + NaCl 5 g + 10% FeCl <sub>3</sub> + Glacial acetic acid-3 ml ST-5 min. Tissue- human skin	The nucleus stained bluish purple colour, which was comparable to the H&E control.	Hibiscus sabdariffa extract will be an alternative to haematoxylin with eosin as a counterstain. (Agbede et al., 2017).
24	Hibiscus sabdariffa	Hibiscus stained reddish brown.	Hibiscus sabdariffa can be considered a histological stain for staining sperm

No.	Dye source, extract, staining solution (SS), staining time (ST), tissues	Observation/Result	Inference, Reference
	Extract- ethanol. SS-1 g extract+ 10 ml of 70% ethanol. ST-20 min. Tissue - rat sperm		(Rosemary B. Bassey et al., 2012).
25	Hibiscus sabdariffa Extract- ethanol SS- extract+ 1% acetic acid + 70% ethanol ST-5,10,15,30, 45, and 60 min Tissue – testis	Hibiscus stained the basophilic parts like spermatogenic cells and the lumen of seminiferous tubules. Best staining was seen in 0.2 concentration, and staining was seen within five min	Hibiscus sabdariffa can be considered a basic dye ( Bassey et al., 2012).
26	Hibiscus sabdariffa Extract - aqueous SS- extract without mordant, extract + Potassium alum, extract + Iron ST-30 min Tissue - testis	Alum mordant-nuclear cytoplasmic differentiation is not good Alum mordant + acetic acid-nuclear cytoplasmic differentiation good, reduced affinity to eosin Alum mordant + ammonia-nuclear cytoplasmic differentiation is poor, with more uptake of eosin Iron mordant + ammonia-nuclear cytoplasmic differentiation is good.	Hibiscus sabdariffa can be a substitute for nuclear staining when mordanted with alum or iron. Enhanced staining is seen when acidified with acetic acid. (Egbujo et al., 2008).
27	Hibiscus sabdariffa Extract – aqueous (20 g /100 ml) Tissue -mice kidney and artery	The cytoplasm of glomeruli and tubules, the cytoplasm of smooth muscle fibres, and RBC stained faint brown colour.	Acidic components, which are separated by chemical purification, can be a better substitute for eosin and can specifically work in cellular components. (Hashim, 2006).
28	Hibiscus sabdariffa Extract – methanol. SS- extract+ potassium alum + glacial acetic acid. Tissue - A. niger, P. notatum and R. stolonifera	The hibiscus extract staining showed better staining than standard lactophenol.	Hibiscus sabdariffa can be a good staining agent for the fungus, which is comparable to lactophenol. (Ihuma J O et al., 2012).
29	Hibiscus sabdariffa Extract- aqueous (50 g /600 ml), 95% alcohol (40 g/500 ml) SS- extract + NH <sub>4</sub> OH, extract + glacial acetic acid, extract alone ST-30 sec and 60 min Tissue - bacteria positive lungs and appendix tissue	The extract stained inflammatory cells better than bacteria.	Any solutions did not demonstrate bacteria well. The change in pH did not affect the staining. (Ma’aruf et al., 2020).
30	Hibiscus rosa-sinensis Extract- aqueous (40 g /500 ml) 80% alcohol (5 g/100 ml) SS- PH at 3.7, 5.7, and 12.7 Tissue- human skin and oral mucosa tissues	The alcoholic extract showed better staining than the aqueous. pH 5.7 showed better staining intensity and contrast.	Hibiscus rosa-sinensis which is easily available and economical and can be used as an alternative to eosin (Sridhara et al., 2016).

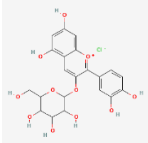
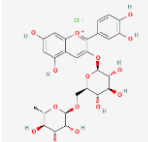
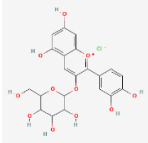
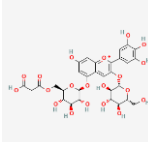


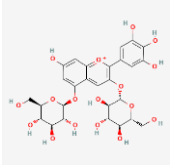
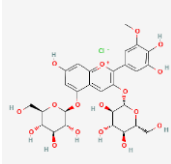
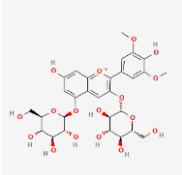
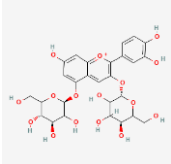
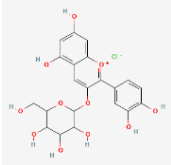
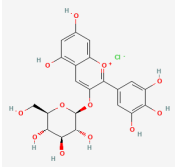
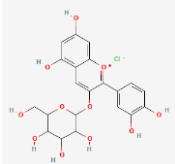
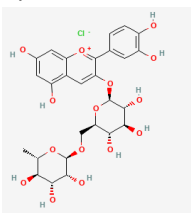
Nearly 60% of the studies used aqueous extracts, 20% used alcoholic extracts and 20% used both aqueous and alcohol extracts of the corresponding plants for staining. A few studies on hibiscus have compared the use of aqueous and alcoholic extracts, where 40% of them concluded that aqueous extracts are superior to alcohol, 20% concluded alcoholic extracts are superior to aqueous, and 40% concluded that there is no significant difference between aqueous and alcoholic extracts. About 46% of the study added mordants to the staining solution, of which an equal percentage used alum or iron. Meanwhile, four studies have used both iron and alum as mordants. In studies that have compared staining with and without mordants, 40% of them mentioned that there are no significant effects of adding alum to the stain. In a comparative study between iron and alum mordants, the former is found to be better than the latter. Almost all studies conducted staining in acidic pH values.

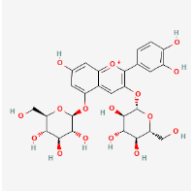
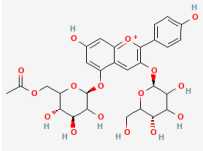
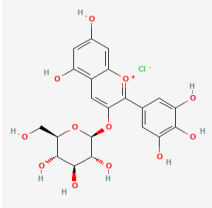
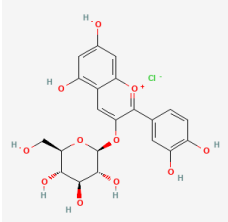
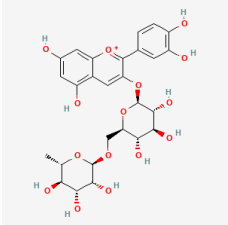
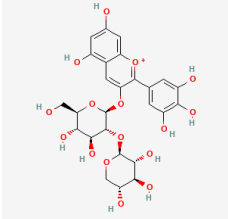
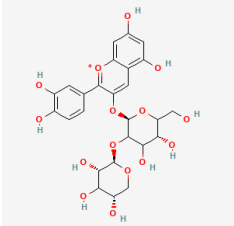
#### 4. Discussion

Anthocyanins are red, purple, or blue pigments that are commonly found in plant parts like fruits, flowers, and tubers (Khoo et al., 2017). Flowers (like hibiscus and rose), fruits (like berries, plum, purple grapes, figs, and black currant), and vegetables (like eggplant, cabbage, etc.) are rich in anthocyanins (Lakshmi, 2014). The common types of anthocyanidins include delphinidin, pelargonidin, cyanidin, petunidin, peonidin, and malvidin (Khoo et al., 2017). The reviewed studies have used ten plants producing anthocyanins, including *Morus nigra*, *Oryza sativa*, *Clitoria ternatea* L, *Syzygium cumini*, *Punica granatum*, *Allium cepa*, *Ixora coccinea* L, *Rosa damascene* and *Rosa hybrida*, *Papaver rhoeas*, *Hibiscus Sabdariffa* and *Hibiscus rosa sinensis*. The types of anthocyanins commonly present in these plants are presented in Table 2.

**Table 2.** Common anthocyanins present in plants featured in the reviewed studies

No.	Plant name, family	Anthocyanin	Reference
1	<i>Morus nigra</i> , Moraceae	Cyanidin-3-glucoside  Cyanidin-3-glucosyl rhamnoside 	(Hassimotto et al., 2007)
2	<i>Oryza sativa</i> , Oryzeae	Cyanide-3-glucoside 	(Pedro et al., 2016)
3	<i>Clitoria ternatea</i> L, Fabaceae	Malonylated delphinidin 3,3'5'-triglucosides  Delphinidin 3-O-(2''-O-α-rhamnosyl-6'-O- β -malonyl-glucoside Delphinidin 3-O-(2''-O-rhamnosyl-6'-O-β-malonyl-glucoside	(Abdullah et al., 2010; Lee & Abdullah, 2011)
4	<i>Syzygium cumini</i> , Myrtaceae	Delphinidin 3,5-diglucoside	( Carmo Brito et al., 2017)

No.	Plant name, family	Anthocyanin	Reference
		 <p>Petunidin 3,5-diglucoside</p>	
		 <p>Malvidin 3,5-diglucoside</p>	
5	Punica granatum, Punicaceae	 <p>Cyanidin-3,5-diglucoside</p>	(Pirzadeh et al., 2020)
		 <p>Cyanidin-3-glucoside</p>	
		 <p>Delphinidin-3-glucoside</p>	
6	Allium cepa, Alliaceae	 <p>Cyanidin 3-glucoside</p>	(Fuleki, 1971; Moosazad et al., 2019)
		 <p>Cyanidin 3-diglucoside</p>	
7	Ixora coccinea, Rubiaceae	 <p>Cyanidin -3-rutinoside</p>	(Patil & Datar, 2015)

No.	Plant name, family	Anthocyanin	Reference
8	Rosa damascene and Rosa hybrid, Rosaceae	Cyanidin 3,5-O-diglucoside 	(Wan et al., 2019)
		Pelargonidin 3,5-di-O-glucoside 	
9	Papaver rhoeas, Papaveraceae	Delphinidin-3-O-glucoside 	(Velickovic et al., 2019)
		Cyanidin-3-O-glucoside 	
		Cyanidin-3-O-rutinoside 	
		Delphinidin-3-sambubioside 	
10	Hibiscus Sabdariffa and Hibiscus rosa-sinensis, Malvaceae	Cyanidine-3-sambubioside 	(Hinojosa-Gómez et al., 2020)

#### 4.1 *Morus nigra*

The various species of mulberry include *Morus alba* (white mulberry), *Morus rubra* (red mulberry), and *Morus nigra* (black mulberry), which produce colours ranging from white to red and black (Hassimotto et al., 2007). *Morus* is a juicy fruit with an acidic character. Glucose and fructose and citric and malic acids are the main sugars and the main organic acids found in *Morus*, respectively (Ozgen et al., 2009). Upon maturity, it becomes dark red to black and has a good staining ability (E. Tousson & Al-Behbehani, 2011). Aqueous extracts of *Morus nigra* have been used to stain nervous tissues, parasites, and sperm (Ebrahimi & Parham, 2020; E. Tousson & Al-Behbehani, 2011; E. M. Tousson & Al-Behbehani, 2010).

Tousson et al. (2010) concluded that *Morus nigra* can be used to stain brain tissues. The stain features various strengths of colours in different areas and cells, like neurons and astrocytes in the brain (Tousson & Al-Behbehani, 2010). Another study by the same authors on liver fluke concluded that *Morus nigra* staining poses more advantages than conventional carmine staining (Tousson & Al-Behbehani, 2011). In both studies, concentrated juices of *Morus nigra* obtained by aqueous extraction (50 g/200 ml) were used. The staining time for brain tissue and liver fluke was 30-60 minutes and 5-10 minutes, respectively. In a similar study, Ebrahimi et al. (2020) stained bull semen with a *Morus nigra* aqueous extract and found that it exhibited red stains with sharp colour contrast. However, the stain could not differentiate between live and dead sperm cells compared with the control stain (Ebrahimi & Parham, 2020). Besides that, a comparative study by Chomean et al. (2019) used *Morus alba* to stain sperm. They concluded that *Morus alba* could visualise sperm's acrosome, middle piece, and tail (Chomean et al., 2019).

*Morus nigra* – among the most deeply coloured stain – has the highest total monomeric anthocyanins, while *Morus alba* has the lowest (Jiang & Nie, 2015). For this reason, the water extract of *Morus nigra* can be used as an alternative to stain sperm, histological tissues, and parasites.

#### 4.2 *Oryza sativa*

There are wide varieties of red and black rice that produce coloured pigments. The dark purple colour of black rice is contributed by the presence of anthocyanin in its pericarp layers (Hiemori et al., 2009). Black rice contains anthocyanins in free forms, which account for 99% of its total anthocyanin (Shao et al., 2014). To stain sperms, aqueous extracts of *Oryza sativa* are added with alum as a mordant (Chomean et al., 2019; Saenguthai et al., 2018). In a study by Saenguthai et al. (2018), a black rice extract was used to highlight spermatozoa in cotton and vaginal swabs. In this study, potassium alum was added to the black rice extract, acting as a mordant. In addition, ethanol and acetic acid were added, as the vaginal swab contains cellular debris and epithelial cells. This same study has also concluded that sex determination may also be done using DNA extracted from the

black rice-stained semen slide for forensic purposes (Saenguthai et al., 2018).

Furthermore, in a study by Chomean et al. (2019) on *Oryza sativa*, *Clitoria ternatea*, *Hibiscus sabdariffa*, and *Morus nigra* for spermatozoa assessment, *Oryza sativa* extracted with ethanol, potash alum, and distilled water was found to be best used for assessing the morphology of spermatozoa. Here, the authors have mentioned that potash alum is a mordant that is necessary for better staining. The positive charge of alum helps to bind the stain molecules with anionic regions like nuclear chromatin. It also helps to improve the intensity of cell and tissue staining. The authors have also mentioned that the purple colour comes from the purple anthocyanin pigment extracted by ethanol (Chomean et al., 2019).

Both studies have given promising results that the water extract of *Oryza sativa* with alum as a mordant can be used for staining sperm.

#### 4.3 *Clitoria ternatea L*

*Clitoria ternatea L* – commonly called butterfly pea – comes in different colours like white, mauve, light blue, and dark blue (Lee & Abdullah, 2011). Seubhkampet and Sotthibandhu (2012) stained blood smears of birds and animals with a *Clitoria ternatea L* extract, with aluminium chloride and ferric chloride as mordants. As anthocyanins are stable in acidic pH, the staining solution used was prepared at pH 0.2. Different types of staining were seen for different cells of the blood smear and are comparable to reference stains. The authors have mentioned that as anthocyanin has a cationic chemical structure, there might have been an interaction between the polynucleotide nucleus and anthocyanin (Suebkhampet & Sotthibandhu, 2012). Nonetheless, a comparative study by Chomean et al. (2019) has produced poor staining of sperm with *Clitoria* extracts.

Anthocyanins in *Clitoria ternatea* produce a range of colours from orange-red, blue, green, and brownish yellow, with pH values ranging from 0.04 to 12 (Abdullah et al., 2010). Besides that, adding co-pigments like catechin has been found to increase the stability of anthocyanins in *Clitoria* (Charurungsipong et al., 2020). In a conclusion, research involving *Clitoria ternatea* with different pH, with the addition of suitable co pigments, suggests that this plant may be an efficient natural dye for staining tissues, smears, etc.

#### 4.4 *Syzygium cumini*

*Syzygium cumini* is an elongated, round, purple-fleshed fruit with a single seed. Anthocyanins are present in the red and purple peels of the fruit, while the green peel does not contain any (Zulfajri & Muttakin, 2018). Suabjakyong et al. (2011) studied the staining efficiency of *Syzygium cumini* when used on rat hepatic tissues. The researchers have created different scenarios by utilising different combinations of dry and fresh fruits, different

solvents like distilled water and 45% glacial acetic acid, with or without ferric alum, and by staining for different durations: 10, 15, and 20 mins. They found that there was no significant staining difference between the groups except for the staining time. Moreover, there was no significant difference in the staining intensity of stained slides and staining solution kept for 14 days. Furthermore, the researchers have also mentioned that the stain has stained both the cytoplasm and nucleus of hepatic tissues with a violet colour. The authors also mentioned that the chemical components of the dye might be non-polar or neutral (Suabjakyong et al., 2011).

Brito et al. (2017) concluded that the best solvent to extract anthocyanins from plum fruits is 95% ethanol with 1% HCl. Additionally, maximum flavylium cation with red colour is observed when the extract has a pH value between 1 to 2 (Brito et al., 2017).

#### 4.5 *Punica granatum*

*Punica granatum* is a round and hexagonal berry fruit, about 5-12 cm in diameter, with reddish and thick skin. In a single *Punica granatum* fruit, there are nearly 600 seeds surrounded by water-laden pulps, with colours varying from white to deep red to purple (Rahimi et al., 2012). Kuskulu and Benli (2017) stained human blood cells using the fruit and obtained orange-brown staining. In another study involving the staining of rat's lung, liver, and heart tissues with *Punica granatum* extract, Kuskulu and Aslan (2019) observed weaker staining compared to H&E staining. Kuskulu et al. stained rat ovary and testis with *Punica granatum* extract of different pH values and temperatures. They found that different colours of staining are observed at the ovary and testis tissues when different temperatures and pH values are used. The researchers concluded that *Punica granatum* extract could be used for staining testis tissues better than ovary tissues for histopathological diagnoses purposes (Kuskulu, 2018).

#### 4.6 *Allium cepa*

In a study by Kuskulu et al. (2017), an aqueous extract of *Allium cepa* was mixed with different mordants like alum, CuSO<sub>4</sub> and FeSO<sub>4</sub> at different temperatures to stain buccal epithelial cells. The researchers found that the cytoplasm was well-stained when no mordant was used, and the nucleus was well-stained when CuSO<sub>4</sub> and FeSO<sub>4</sub> were used as mordants (Kuskulu et al., 2017).

According to Hashem et al., anthocyanins from *Allium cepa*'s skin extracted by both acidified methanol and ethanol at 40°C to 80°C were found to be more stable than other anthocyanins (Ali et al., 2016).

#### 4.7 *Ixora coccinea*

The flowers of *Ixora coccinea* are corymbiform, dense, actinomorphic, pedunculated, or sessile cymes (Gopalkrishnan & Chiranjeev, 2018). Cruz et al. (2018) stained blood smears with an extract from *Ixora coccinea*'s flowers. In this study, an ethanol

extract was used in 25% and 36% concentrations. Even though the 25% ethanol extract was better than the 36% one, the authors found that *Ixora coccinea* is not an effective stain for staining blood smears. They have recommended a few suggestions to improve the results, including using soxhlet extractions, mechanical compression of flowers, monitoring the pH, maintaining standard staining time, and increasing the concentration of extracts (Cruz et al., 2018).

Additionally, in a study by Patil and Datar (2015), it was found that the *Ixora coccinea* extract was stable at low pH values, where the stability was affected by light and temperature (Patil & Datar, 2015).

#### 4.8 *Rosa damascene and Rosa hybrid*

There are more than 100 species of plants within the *Rosa* genus that belong to the *Rosaceae* family (Kumar et al., 2015). *Rosa damascene* is grown in gardens as decorative plant. They produce flowers of different colours ranging from white, pink, yellow, purple, and red (Kamal, 2018). An alcoholic extract of *Rosa damascene* has been used by Kamal et al. (2018) to stain a Leishmania parasite sample that became red in colour. Another study by Kumar et al. (2015) involved the use of an aqueous and alcoholic extract of *Rosa hybrida* and *Hibiscus sabdariffa* to stain helminth parasite samples. This study found that *Rosa hybrida* stains were better than *Hibiscus sabdariffa* (Kumar et al., 2015). On the other hand, Surendra et al. (2018) stained normal and pathological oral tissues with rose stains extracted using maceration and soxhlet methods with or without adding potassium alum. The researchers concluded that soxhlet extract with the addition of potassium alum as mordants exhibited better staining properties compared to other groups (Surendra et al., 2018).

#### 4.9 *Papaver rhoeas*

*Papaver rhoeas* is a deep red-coloured flower with large and thin petals. The petal base is a black-coloured area that is bordered by white lines (van der Kooi & Stavenga, 2019). Budak and Budak (2015) stained lung and liver tissues with a *Papaver* stain prepared by adding mordants and a solvent with a weak acid, oxidant, and antioxidant. The slides demonstrated good staining of the nucleus, which was depicted as clear and well-defined. The stain was dark purple in colour and was depicted in the images seen in the article. From this observation, the researchers concluded that *Papaver rhoeas* might be used as an alternative for haematoxylin stains. The *Papaver rhoeas* stain was red when added to the slide. Upon bluing with tap water, it turned blue. A similar principle was also observed in haematoxylin staining. Because of these properties, *Papaver rhoeas* stain may be a better alternative to haematoxylin stains (Budak & Budak, 2015).

Meanwhile, Ekici (2014) demonstrated that the maximum concentration of anthocyanin in *Papaver rhoeas* was obtained by concentrating the extract using a vacuum evaporation method.

The degradation of anthocyanin was found to be higher when the conventional method of concentration was used compared to microwave and vacuum approaches. The researchers also mentioned that temperature increase had accelerated anthocyanin degradation in *Papaver rhoeas* flower extracts (Ekici, 2014).

#### 4.10 *Hibiscus sabdariffa* and *Hibiscus rosa-sinensis*

The phytochemical constituents of hibiscus include phenolic compounds, flavonoids, anthocyanin, and protocatechuic acid. The most abundant phytochemical of the above is anthocyanin (Ademiluyi et al., 2013). A hibiscus extract with more than 20% concentration solidifies when boiled due to the presence of pectin (Hashim, 2006). Many studies have been done to examine the staining effects of hibiscus on parasites, fungi, bacteria, animal and human tissues.

##### 4.10.1 Parasites

Kamal (2018), in their study stained *Leishmania* with water and alcoholic hibiscus extracts, which produced pink and bluish-pink stains, respectively (Kamal, 2018).

##### 4.10.2 Fungi

Abubakar et al. (2012) stained a few fungal species with both aqueous and alcoholic extracts and found that the staining was similar to the standard lactophenol and methylene blue stains, except for the red colour. The authors also mentioned that aqueous extracts are superior in staining compared to alcoholic ones (Abubakar et al., 2012). Ihuma et al. (2012) stained a few fungal species with a methanolic extract of hibiscus. They found that the staining was better than lactophenol. The authors also mentioned that since methanolic extract (Ph-2.7) and lactophenol (Ph-3.6) are acidic, the staining is similar (Ihuma et al., 2012).

##### 4.10.3 Bacteria

Ma'aruf et al. (2020) made an attempt at staining bacteria found in lung and appendix tissues with different extracts but did not achieve their objectives. They concluded that inflammatory cells are stained better than bacteria (Ma'aruf et al., 2020). Furthermore, hibiscus was found to be more soluble in alcohol than in water. In this study, the use of aqueous extracts and staining for a shorter duration demonstrated better staining potentials (Ma'aruf et al., 2020).

##### 4.10.4 Tissue histology

Hibiscus has been used in histological staining as a nuclear (substitute for haematoxylin) and cytoplasmic stain (substitute for eosin).

##### 4.10.5 Tissue histology (Nuclear stain)

Bernard et al. (2017) and Agbede et al. (2017) used an aqueous hibiscus extract to stain nuclei as a substitute for haematoxylin in H&E staining. In this context, the solvent is prepared by adding NaCl, 10% FeCl<sub>3</sub>, and glacial acetic acid into the extract. The nuclear staining results turned out to be similar

to haematoxylin. The authors concluded that hibiscus is a good nuclear stain for brain tissues, skin, lymph nodes, and appendix tissues (Agbede et al., 2017; Benard et al., 2017; Benard et al., 2015; Benard, 2008). Meanwhile, Egbujo et al. (2008) stained testicular tissues with an aqueous extract of hibiscus with different mordants like alum and iron. The researchers also added acetic acid or ammonia to alter the extract's pH values. They found good nuclear-cytoplasmic differentiation with iron mordant. At the same time, acetic acid was also found to enhance the staining. Iron mordant was better than alum, as the former was able to also highlight the connective tissues. This might be due to the fact that the dye lake bond formed by iron alum is stronger than potassium alum (Egbujo et al., 2008). On top of that, Bassey et al. (2012) stained testicular tissues and sperms with an alcoholic extract of hibiscus mixed with 70% ethanol. They concluded that hibiscus might act as a basic dye (Bassey et al., 2012).

##### 4.10.6 Tissue histology (Cytoplasmic stain)

Hashim (2006) stained kidney and artery tissues with aqueous extract as a substitute for eosin. As a result, faint brown staining was obtained in the cytoplasm of renal glomeruli and tubules (Hashim, 2006). Besides that, Gowali (1995) stained biopsies from muscular dystrophy and cardiac myo infarction patients with a combination of picric acid and hibiscus stain. This extract could differentiate between intact and necrotic muscle fibres using different colours. In this study, staining was done according to the principle and method of Masson trichrome staining. Steps like treating with 1% iron alum and mordanting with 5% phosphotungstic acid were also included in the procedure. This study shows that hibiscus may also be used as a differential stain (Gowali, 1995). Furthermore, Sridhara et al. (2016) used both alcoholic and aqueous hibiscus extracts with different pH values to stain oral mucosa and skin tissue blocks. The researchers found that there was no statistical significance in staining parameters between hibiscus and H&E staining. The study has also concluded that alcoholic extracts (5.7 pH) demonstrated better staining than aqueous ones (Sridhara et al., 2016).

Studies that used hibiscus as a substitute for haematoxylin have mostly used acetic acid as one of the constituents. Moreover, both ethanolic and aqueous extracts have been used as nuclear and cytoplasmic stains. Hibiscus may also be used as a nuclear and cytoplasmic stain, depending on the stain it replaces in the procedure.

#### 4.11 *Factors influencing histology staining*

The ability of dyes to stain tissues is influenced by the affinities between the two. The dye-tissue affinity depends on many factors like coulombic attractions, Van der Waal's forces, hydrogen bonding, and covalent bonding between the tissue and the reagent (dye) (Suvarna et al., 2013; Veuthey et al., 2014).

Stains containing anthocyanin can be used as substitutes for synthetic stains to stain histological tissues, microorganisms,



smears, etc. The staining effect depends on the plant products, type of extract, the concentration of anthocyanin, pH value of the staining solutions, temperature, use of mordants, etc.

Even though most of the reviewed studies have been done using aqueous extracts, there is essentially not much significant difference between aqueous and alcoholic ones. This is because, since anthocyanins are polar molecules, the common solvents used for extraction purposes are aqueous mixtures of ethanol, methanol, and acetone. These methods will also extract other non-phenolic substances like organic acids, sugar, and proteins which require a further purification process. Besides that, acidified methanol or ethanol is also commonly used for extraction (Awika et al., 2005; Cacace & Mazza, 2003; Fossen & Andersen, 2003). This might also be the reason why many studies have added a small percentage of glacial acetic acid to their solvents. The addition of strong acid should be avoided, as it might degrade the acylated anthocyanin and destroy the glycoside bond in anthocyanins (Castañeda et al., 2009).

#### 4.11.1 The Effect of pH on Histology Staining

Almost all studies involve staining under acidic pH. Flavylium ions are more predominant at pH one and produce a red or purple colour. At pH 2 to 4, quinoidal bases are more predominant, producing a blue colour. Meanwhile, at pH 5 and 6, two colourless specie like chalcone and carbinol pseudo base are produced. When the pH exceeds 7, the anthocyanins are degraded. At pH 4 to 6, the four structural forms – anhydrous quinoidal base, yellow chalcone, colourless carbinol, and flavylium cation – exist together. For this reason, anthocyanin's colour changes are more prominent in alkaline solutions (Cabrita et al., 2000; Castañeda et al., 2009). According to Budak and Budak (2015), the addition of a weak acid to the solvent will help to adjust the pH between 2 and 3.7, and provide a more stable and effective composition. The other uses of acids include acting as a buffer and prolonging the shelf life of the solution. It also increases the selectivity of nuclei and prevents over-oxidation (Budak & Budak, 2015).

Additionally, specific staining of tissue structures by the dye also depends on the pH of the extract. Acidic and basic stains are used for staining basic and acidic structures, respectively. The charge distribution in the dyes determines their repulsive and attractive nature. Anions with negative charges are attracted to positively-charged molecules, while cations with positive charges are attracted to negatively-charged molecules. Therefore, charges are greatly determined by the pH of the dye. Low pH solutions increase the number of charged groups within the tissues and vice versa. Hence, the pH of the extract is an imperative factor that determines the dye's staining effect (Kumar et al., 2015; Avwioro, 2002; Avwioro, 2010).

#### 4.11.2 Effect of Mordants on Histology Staining

Iron or alum mordants are used in many studies to improve the staining effects. One main characteristic of anthocyanins that have *O*-di-hydroxyl groups in their ring is their capacity to form

metal-anthocyanin complexes (Boulton, 2001). A few studies on the colour stability of anthocyanins have suggested that the blue colour is attributed to the complexation observed between anthocyanins and metals like Al, Fe, Cu, etc. The complexation formed by Al (III)-anthocyanin interaction stabilizes the blue quinoidal base, a process that prevents its oxidation (Moncada et al., 2003). Recent studies have also shown that the complexation process between Fe (III) and *O*-di-hydroxyl groups at pH 5 is necessary for the formation of the blue colour (Castañeda et al., 2009; Yoshida et al., 2006).

Anthocyanin-based natural stains have good potential to replace synthetic stains used in histopathological diagnosis. None of the studies talk about the stability of natural staining solutions as well as its fading tendency in slides. For this reason, there is a gap in the literature for researchers to fill by exploring the natural anthocyanin chemistry, isolation from plants, and optimizing appropriate staining medium with mordants at suitable pH, solubility, and stability.

## 5. Conclusion

*Oryza sativa* aqueous extracts with potassium alum as mordant can be used for staining semen to allow researchers to observe the morphology of sperms. Aqueous extract of *Papaver rhoeas* with added chemicals like acetified ethylene glycol, sodium iodide, aluminium chloride, beta-cyclodextrin, and potassium alum can act as a good alternative stain to haematoxylin, as they both share the same staining principle. Besides that, *Hibiscus sabdariffa* and *Rosa hybrida* aqueous extracts with the presence of iron or alum as mordant can also be used for histopathological staining. Further studies are needed to investigate the effectiveness of *Morus nigra*, *Clitoria ternatea*, *Allium cepa*, *Syzygium cumini*, and *Punica granatum* by using different solvents to increase their staining potentials when used on various histological tissues. There is a lack of studies that analyze the stability of slides stained with natural stains, which is a very important requirement for histopathology. These lacunae presents a space for the discovery and invention of new natural stains.

## 6. References

- Abdullah, R., Lee, P. M., & Lee, K. H. (2010). Multiple colours and pH stability of floral anthocyanin extract: *Clitoria ternatea*. 2010 International Conference on Science and Social Research 254–258.
- Abubakar, S., Usman, A. B., Etim, V., Nnadi, O., & Alaku, C. (2012). Application of Organic Dyes from Roselle calyx (*Hibiscus sabdariffa* linn) for Mycological Staining. *Indian Journal of Innovations and Developments* 1(9): 687–690.
- Ademiluyi, A. O., Oboh, G., & Oluwaseun, A. J. (2013). Anthocyanin – Rich Red Dye of *Hibiscus sabdariffa* calyx Modulates Cisplatin-induced Nephrotoxicity and

- Oxidative Stress in Rats. *International Journal of Biomedical Science* 9(4) 243–248.
- Agbede, M. B., Benard, S. A., Afolabi, O. O., Okoye, J. O., Bankole, J. K., Fowotade, A. A., Olutunde, O. A., & Muhammed, O. A. (2017). The Use of Hibiscus sabdariffa Extract as Nuclear Stain for Skin Morphology and Connective Tissue with Eosin Counterstain. *Sokoto Journal of Medical Laboratory Science* 2(4), 28–32.
- Ajileye, A. B., Iteire, A. K., & Arigi, Q. B. (2015). Zingiber officinale (ginger) extract as a histological dye for muscle fibers and cytoplasm. *International Journal of Medical Science and Public Health* 4(10): 1445–1448.
- Akinloye, A. J., & Olagoke, A. (2010). Screening of some indigenous herbal dyes for use in plant histological staining. *Journal of Forestry Research* 21(1): 81–84.
- Ali, O.-H., Al-sayed, H., Yasin, N., & Afifi, E. (2016). Effect of Different Extraction Methods on Stability of Anthocyanins Extracted from Red Onion peels (*Allium cepa*) and Its Uses as Food Colorants. *Bulletin of the National Nutrition Institute* 47(2): 196–219. <https://doi.org/10.21608/bnni.2016.4218>
- Anonymous. (2020). IARC Monographs on the Identification of Carcinogenic Hazards to Humans – International Agency for research on cancer. WHO. <https://monographs.iarc.fr/>
- Avwioro, G. O. (2002). *Histochemistry and Tissue Pathology*, pp.134-213, Abraka, Nigeria: University press.
- Avwioro, G. O. (2010). *Histochemistry and tissue pathology, principles and techniques*, pp.561-568 Abraka, Nigeria: University press.
- Awika, J. M., Rooney, L. W., & Waniska, R. D. (2005). Anthocyanins from black sorghum and their antioxidant properties. *Food Chemistry* 90(1–2): 293–301.
- Bassey, R. B., Bakare, A. A., Peter, A. I., Oremosu, A. A., & Osinubi, A. A. (2012). Factors influencing extract of Hibiscus sabdariffa staining of rat testes. *Biotechnic and Histochemistry* 87(6): 403–407. <https://doi.org/10.3109/10520295.2012.679365>
- Bassey, Rosemary B., Osinubi, A. A., & Oremosu, A. A. (2012). Staining effect of Hibiscus sabdariffa extract on sperm cell morphology of Sprague-Dawley rats. *Journal of Histotechnology* 35(3): 110–113. <https://doi.org/10.1179/2046023612Y.0000000010>
- Benard, S., Afolabi, O., Fowotade, A., Okoye, J., Olutunde, O., & Bankole, J. (2017). Hibiscus-Van Gieson Stain for collagen fibers. *African Journal of Cellular Pathology* 9: 1–4.
- Benard, S., Muhammed, A., Fowotade, A., Afolabi, O., & Olutunde, O. (2017). Iron-Roselle: A Progressive Nuclear Stain for Connective Tissue of Skin. *International Journal of Health Research and Innovation* 5(2): 25–31.
- Benard, S A, Muhammaed, A., Fowotade A A, Afolabi O O, & Olutunde, O. A. (2015). Hibiscus sabdariffa extract as haematoxylin substitute in the histological demonstration of brain tissues. *African Journal of Cellular Pathology* 5: 32–35.
- Benard, Solomon A. (2008). Iron-roselle: A progressive nuclear stain substitute for haematoxylin. *Journal of Histotechnology* 31(2): 57–59. <https://doi.org/10.1179/his.2008.31.2.57>
- Bondoc, C. C. (2018). Curcuma longa Linn rhizome extract as an alternative stain for histological studies. *Journal of Pharmacognosy and Phytochemistry* 7(5): 3010–3017.
- Bordoloi, B., Jaiswal, R., Siddiqui, S., & Tandon, A. (2017). Health Hazards of Special Stains. *Saudi Journal of Pathology and Microbiology* 2(5): 175–178.
- Boulton, R. (2001). The Copigmentation of Anthocyanins and Its Role in the Color of Red Wine: A Critical Review. *American Journal of Enology and Viticulture* 52(2): 67–87.
- Budak, M., & Budak, G. G. (2015). A new biochemical dye molecule and nuclear stain formulation in histotechnology diagnostics as an alternative to haematoxylin. *Journal of Histotechnology* 38(4): 113–121. <https://doi.org/10.1179/2046023615Y.0000000009>
- Cabrita, L., Fossen, T., & Andersen, Ø. M. (2000). Colour and stability of the six common anthocyanidin 3-glucosides in aqueous solutions. *Food Chemistry* 68(1): 101–107. [https://doi.org/10.1016/S0308-8146\(99\)00170-3](https://doi.org/10.1016/S0308-8146(99)00170-3)
- Cacace, J. E., & Mazza, G. (2003). Mass transfer process during extraction of phenolic compounds from milled berries. *Journal of Food Engineering* 59(4): 379–389. [https://doi.org/10.1016/S0260-8774\(02\)00497-1](https://doi.org/10.1016/S0260-8774(02)00497-1)
- Castañeda, A., Hernández, L. P., Elena, P., Rodríguez, J. A., & Galán-Vidal, C. A. (2009). Chemical studies of anthocyanins: A review. *Food Chemistry* 113(4): 859–871. <https://doi.org/10.1016/j.foodchem.2008.09.001>

- Charurungsipong, P., Tangduangdee, C., Amornraksa, S., Asavasanti, S., & Lin, J. (2020). Improvement of Anthocyanin Stability in Butterfly Pea Flower Extract by Co-pigmentation with Catechin. *E3S Web of Conferences*, 141(9). <https://doi.org/10.1051/E3SCONF/202014103008>
- Chomean, S., Nantabut, M., Kongtia, W., Saenguthai, K., & Kaset, C. (2019). Evaluation of natural dyes for human spermatozoa morphology assessment. *Acta Histochemica* 121(2): 227–233. <https://doi.org/10.1016/j.acthis.2018.12.010>
- Cruz, P. E., De Vera, A. P., & Villa, A. D. (2018). The efficiency of Santan flower (*Ixora occinea* Linn.) as an alternative stain to eosinY in Wright-Giemsa stain. *LPU-Laguna Journal of Allied Medicine* 3(1): 11–21.
- Dapson, R., Horobin, R. W., & Kiernan, J. A. (2010). Hematoxylin shortages: Their causes and duration, and other dyes that can replace hemalum in routine haematoxylin and eosin staining. *Biotechnic and Histochemistry* 85(1): 55–63. <https://doi.org/10.3109/10520290903048400>
- Dela, G., Or, E., Ovadia, R., Nissim-Levi, A., Weiss, D., & Oren-Shamir, M. (2003). Changes in anthocyanin concentration and composition in “Jaguar” rose flowers due to transient high-temperature conditions. *Plant Science* 164(3): 333–340. [https://doi.org/10.1016/S0168-9452\(02\)00417-X](https://doi.org/10.1016/S0168-9452(02)00417-X)
- do Carmo Brito, B. de N., da Silva Pena, R., Santos Lopes, A., & Campos Chiste, R. (2017). Anthocyanins of Jambolao (*Syzygium cumini*): Extraction and pH-Dependent Colour Changes. *Journal of Food Science* 82(10): 2286–2290. <https://doi.org/10.1111/1750-3841.13847>
- Ebrahimi, M., & Parham, A. (2020). Using Herbal dyes as an alternative staining method for sperm evaluation. *Veterinary Medicine and Science* 6: 441–446. <https://doi.org/10.1002/vms3.268>
- Egbujo, E. C., Adisa, O. J., & Yahaya, A. B. (2008). A Study of the Staining Effect of Roselle (*Hibiscus sabdariffa*) on the Histologic Section of the Testis. *International Journal of Morphology* 26(4): 927–930. <https://doi.org/10.4067/S0717-95022008000400022>
- Ekici, L. (2014). Effects of concentration methods on bioactivity and colour properties of poppy (*Papaver rhoeas* L.) sorbet, a traditional Turkish beverage. *LWT - Food Science and Technology* 56(1): 40–48. <https://doi.org/10.1016/j.lwt.2013.11.015>
- Fossen, T., & Andersen, Ø. M. (2003). Anthocyanins from red onion, *Allium cepa*, with novel aglycone. *Phytochemistry* 62(8): 1217–1220.
- Fuleki, T. (1971). Anthocyanins in red onion, *Allium cepa*. *Journal of Food Science* 36(1): 101–104.
- Gopalkrishnan, B., & Chiranjeev, R. (2018). Pharmacognostical study of *Ixora coccinea* flower. *Pharmacognosy Journal* 10(5): 1042–1046. <https://doi.org/10.5530/pj.2018.5.176>
- Gowali, F. M. (1995). Picro-Hibiscin Stain for Degenerated Muscle Fibers. *Laboratory Medicine* 26(7): 470–473. <https://doi.org/10.1093/LABMED/26.7.470>
- Hashim, E. A. (2006). The use of watery extract of kujarat flowers *Hibiscus sabdariffa* as a natural histological stain. *Iraqi Journal of Medical Science* 5(1): 29–33.
- Hassimotto, N. M. A., Genovese, M. I., & Lajolo, F. M. (2007). Identification and characterisation of anthocyanins from wild mulberry (*Morus nigra* L.) growing in Brazil. *Food Science and Technology International* 13(1): 17–25. <https://doi.org/10.1177/1082013207075602>
- Hiemori, M., Koh, E., & Mitchell, A. E. (2009). Influence of cooking on anthocyanins in black rice (*Oryza sativa* L. japonica var. SBR). *Journal of Agricultural and Food Chemistry* 57(5): 1908–1914. <https://doi.org/10.1021/jf803153z>
- Hinojosa-Gómez, J., San Martín-Hernández, C., Heredia, J. B., León-Félix, J., Osuna-Enciso, T., & Muy-Rangel, M. D. (2020). Anthocyanin Induction by Drought Stress in the Calyx of Roselle Cultivars. *Molecules* 25(7): 1555. <https://doi.org/10.3390/molecules25071555>
- Hou, Z., Qin, P., Zhang, Y., Cui, S., & Ren, G. (2013). Identification of anthocyanins isolated from black rice (*Oryza sativa* L.) and their degradation kinetics. *Food Research International* 50(2): 691–697. <https://doi.org/10.1016/j.foodres.2011.07.037>
- Ihuma J O, Asenge, G. H., Abioye, J. O. K., & Dick, S. K. (2012). Application of methonolic extracts from *Hibiscus sabdariffa* linn as a biological staining agent for some fungal species. *International Journal of Plant Animal and Environmental Sciences* 2(2): 254–259.
- Jiang, Y., & Nie, W. J. (2015). Chemical properties in fruits of mulberry species from the Xinjiang province of China. *Food Chemistry* 174: 460–466. <https://doi.org/10.1016/j.foodchem.2014.11.083>

- Kamal, S. B. (2018). Staining of *Leishmania donavani* Promastigotes by natural flower dyes. *Pakistan Journal of Biotechnology* 15(2): 299–302.
- Khoo, H. E., Azlan, A., Tang, S. T., & Lim, S. M. (2017). Anthocyanidins and anthocyanins: Coloured pigments as food, pharmaceutical ingredients, and the potential health benefits. *Food and Nutrition Research* 61(1). <https://doi.org/10.1080/16546628.2017.1361779>
- Kumar, N., Mehul, J., Das, B., & Solanki, J. B. (2015). Staining of Platyhelminthes by herbal dyes: An eco-friendly technique for the taxonomist. *Veterinary World* 8(11): 1321–1325. <https://doi.org/10.14202/vetworld.2015.1321-1325>
- Kusculu, N. G., & Aslan, H. G. (2019). Evaluation of an extract of the *Punica granatum* flower as a biological stain of rat tissues: A preliminary study. *Molecular Biology Reports* 46(1): 581–585. <https://doi.org/10.1007/S11033-018-4510-3>
- Kusculuo, N. G. (2018). Evaluation and comparison of staining effect of *Punica granatum* flower extract on testis and ovary of Wistar rats: First results. *African Journal of Biotechnology* 17(32): 989–993. <https://doi.org/10.5897/ajb2018.16535>
- Kusculuo, N. G., Cucer, N., & Onal, A. (2017). Staining of Onion and Buccal Epithelial Cells with Onion Skin Extract | Open Access Journals. *Research & Reviews: Research Journal of Biology* 5(2): 1–6.
- Kuskuluo, N. G., & Benli, H. (2017). Staining Effect of Pomegranate Flower Extract on Human Blood Cells: First Results. *Journal of Environmental Science and Engineering* 6:249–251.
- Lahiani, A., Klaiman, E., & Grimm, O. (2018). Enabling Histopathological Annotations on Immunofluorescent Images through Virtualization of Haematoxylin and Eosin. *Journal of Pathology Informatics*, 9: 1. <https://www.ncbi.nlm.nih.gov/pmc/articles/PMC5841016/>
- Lakshmi, C. (2014). Food Colouring: The Natural Way. *Research Journal of Chemical Sciences*, 4(2): 87–96. [www.isca.me](http://www.isca.me)
- Lee, P. M., & Abdullah, R. (2011). Thermal Degradation of Blue Anthocyanin Extract of *Clitoria ternatea* Flower. 2nd International Conference on Biotechnology and Food Science 49–53.
- Ma'aruf, S. Y., Mohammed, M. O., Muhammad, A. T., Okechi, O. O., Tsamiya, R. I., Abubakar, U., Mohammed, I., Umar, A., Sani, S. M., Kabir, H., Bello, B. A., Garba, S., & Abubakar, S. D. (2020). Staining Property of Alcoholic and Aqueous *Hibiscus sabdariffa* Extract in Demonstration of Selected Bacteria in Tissue Sections of Wistar Rats. *Microbiology Research Journal International* 30(2), 26–33.
- Mat Nor, N. A., & Arof, A. K. (2016). On statistical analysis of factors affecting anthocyanin extraction from *Ixora siamensis*. *Optical Materials* 60: 462–466. <https://doi.org/10.1016/j.optmat.2016.08.034>
- Mohandas, R., Ramani, P., Sherlin j, H., Gheena, S., Ramasubramanian, A., Don, K. R., Jayaraj, G., & Santhanam, A. (2019). Organic stains used in histopathology-A systematic review. *Drug Invention Today* 11: 426–432.
- Moncada, M. C., Moura, S., Melo, M. J., Roque, A., Lodeiro, C., & Pina, F. (2003). Complexation of aluminum (III) by anthocyanins and synthetic flavylum salts: A source for blue and purple colour. *Inorganica Chimica Acta* 356: 51–61. [https://doi.org/10.1016/S0020-1693\(03\)00394-3](https://doi.org/10.1016/S0020-1693(03)00394-3)
- Moosazad, S., Ghajarbeigi, P., Mahmoudi, R., Shahsavari, S., Vahidi, R., & Soltani, A. (2019). Antibacterial and Antioxidant Properties of Colorant Extracted from Red Onion Skin. *Journal of Chemical Health Risks*, 9(3): 235–243. <https://www.magiran.com/paper/2038588>
- Ozgen, M., Serce, S., & Kaya, C. (2009). Phytochemical and antioxidant properties of anthocyanin-rich *Morus nigra* and *Morus rubra* fruits. *Scientia Horticulturae*, 119(3): 275–279. <https://doi.org/10.1016/j.scienta.2008.08.007>
- Patil, N., & Datar, A. G. (2015). Extraction, stability and separation of anthocyanins of *Ixora coccinea* linn. *International Journal of Pharmacy and Pharmaceutical Sciences* 7(3): 198–202.
- Pedro, A. C., Granato, D., & Rosso, N. D. (2016). Extraction of anthocyanins and polyphenols from black rice (*Oryza sativa* L.) by modeling and assessing their reversibility and stability. *Food Chemistry* 191: 12–20. <https://doi.org/10.1016/j.foodchem.2015.02.045>
- Pirzadeh, M., Caporaso, N., Rauf, A., Shariati, M. A., Yessimbekov, Z., Khan, M. U., Imran, M., & Mubarak, M. S. (2021). Pomegranate as a source of bioactive constituents: A review on their characterization, properties and applications. *Critical Reviews in Food Science and Nutrition* 61(6):982-999. <https://doi.org/10.1080/10408398.2020.1749825>

- Quina, F. H., Moreira, P. F., Vautier-Giongo, C., Rettori, D., Rodrigues, R. F., Freitas, A. A., Silva, P. F., & Maçanita, A. L. (2009). Photochemistry of anthocyanins and their biological role in plant tissues. *Pure and Applied Chemistry* 81(9): 1687–1694. <https://doi.org/10.1351/PAC-CON-08-09-28>
- Rahimi, H. R., Arastoo, M., & Ostad, S. N. (2012). A comprehensive review of *Punica granatum* (Pomegranate) properties in toxicological, pharmacological, cellular and molecular biology researches. *Iranian Journal of Pharmaceutical Research* 11(2): 385–400. <https://doi.org/10.22037/ijpr.2012.1148>
- Ramamoorthy, A., Ravi, S., Jeddy, N., Thangavelu, R., & Janardhanan, S. (2016). Natural alternatives for chemicals used in histopathology lab- A literature review. In *Journal of Clinical and Diagnostic Research* 10(11): EE01-EE04. <https://doi.org/10.7860/JCDR/2016/23420.8860>
- Saenguthai, K., Chomean, S., & Kaset, C. (2018). The evaluation of *Oryza sativa* L. (Black rice) extracts for detection of spermatozoa on the clothing and vaginal swab samples. *Legal Medicine* 35: 91–97. <https://doi.org/10.1016/j.legalmed.2018.09.020>
- Shaik, A., Naidu, K. K., & Panda, J. (2018). A review on anthocyanins: A promising role on phytochemistry and pharmacology. *International Research Journal of Pharmacy* 9(1): 1–9.
- Shao, Y., Xu, F., Sun, X., Bao, J., & Beta, T. (2014). Phenolic acids, anthocyanins, and antioxidant capacity in rice (*Oryza sativa* L.) grains at four stages of development after flowering. *Food Chemistry* 143: 90–96. <https://doi.org/10.1016/j.foodchem.2013.07.042>
- Singh, R. (2017). Sources of natural dye-A critical review. *International Journal of Engineering, Science and Mathematics* 6(5): 180–186.
- Siva, R. (2007). Status of natural dyes and dye-yielding plants in India. *Current Science* 92(7): 916–925.
- Sridhara, S. U., Raju, S., Gopalkrishna, A. H., Haragannavar, V. C., Latha, D., & Mirshad, R. (2016). Hibiscus: A different hue in histopathology. *Journal of Medicine Radiology Pathology and Surgery* 2: 9–11.
- Suabjakyong, P., Romratanapun, S., & Thitipramote, N. (2011). Extraction of Natural Histological Dye from Black Plum Fruit (*Syzygium cumini*). *Journal of the Microscopy Society of Thailand* 4(1): 13–15.
- Sudhakaran, A., Hallikeri, K., & Babu, B. (2018). Natural stains *Zingiber officinale* Roscoe (ginger) and *Curcuma longa* L. (turmeric) – A substitute to eosin. *AYU* 39(4): 220–225. [https://doi.org/10.4103/ayu.ayu\\_232\\_17](https://doi.org/10.4103/ayu.ayu_232_17)
- Suebkhampet, A., & Sotthibandhu, P. (2012). Effect of using aqueous crude extract from butterfly pea flowers (*Clitoria ternata* L.) as a dye on animal blood smear staining. *Suranaree Journal of Science and Technology* 19(1): 15–19.
- Surendra, L., Nambiar, K. S., Haragannavar, V. C., Augustine, D., Sowmya, S. V., Babu, A., & Rao, R. S. (2018). Staining efficacy of rose extract in comparison with eosin stain: A histological study on oral tissues. *World Journal of Dentistry* 9(6): 500–504. <https://doi.org/10.5005/jp-journals-10015-1587>
- Suvarna, K., Layton, C., & Bancroft, J. (2013). *Bancroft's Theory and Practice of Histological Techniques* (7th ed.). Churchill Livingstone Elsevier.
- Tousson, E., & Al-Behbehani, B. (2011). Black mulberries (*Morus nigra*) as a natural dye for animal tissues staining. *Animal Biology* 61(1): 49–56.
- Tousson, E. M., & Al-Behbehani, B. (2010). Black Mulberries (*Morus nigra*) as a natural dye for nervous tissues staining. *The Egyptian Journal of Experimental Biology (Zoology)* 6(1): 159–164.
- van der Kooi, C. J., & Stavenga, D. G. (2019). Vividly coloured poppy flowers due to dense pigmentation and strong scattering in thin petals. *Journal of Comparative Physiology A: Neuroethology, Sensory, Neural, and Behavioral Physiology* 205(3): 363–372. <https://doi.org/10.1007/s00359-018-01313-1>
- Vankar, P. S. (2000). Chemistry of Natural Dyes. *Resonance* 5(10): 73–80.
- Velickovic, J. M., Mitic, M. N., Arsic, B. B., Paunovic, D. Đ., Stojanovic, T., Veljkovic, J. N., Dimitrijevic, D. S., Stevanovic, S. D., & Kostic, D. A. (2019). HPLC Analysis of extracts of fresh petals of *Papaver rhoeas* L. *Studia Universitatis Babeş-Bolyai, Chemia* 3: 239–247. <https://doi.org/10.24193/subbchem.2019.3.20>
- Verma, S., & Gupta, G. (2017). Natural dyes and its applications: A brief review. *International Journal of Research and Analytical Reviews* 4(4): 57–60.
- Veuthey, T. V., Herrera, G. M., & Doderio, V. I. (2014). Dyes and stains: From molecular structure to histological application. *Frontiers in Bioscience* 19(1): 91–112. <https://doi.org/10.2741/4197>

- Wahyuningsih, S., Wulandari, L., Wartono, M. W., Munawaroh, H., & Ramelan, A. H. (2017). The Effect of pH and Color Stability of Anthocyanin on Food Colorant. IOP Conference Series: Materials Science and Engineering 193(1). <https://doi.org/10.1088/1757-899X/193/1/012047>
- Wan, H., Yu, C., Han, Y., Guo, X., Luo, L., Pan, H., Zheng, T., Wang, J., Cheng, T., & Zhang, Q. (2019). Determination of flavonoids and carotenoids and their contributions to various colours of rose cultivars (*Rosa* spp.). *Frontiers in Plant Science* 10: 123. <https://doi.org/10.3389/fpls.2019.00123>
- Yoshida, K., Kitahara, S., Ito, D., & Kondo, T. (2006). Ferric ions involved in the flower colour development of the Himalayan blue poppy, *Meconopsis grandis*. *Phytochemistry* 67(10): 992–998. <https://doi.org/10.1016/J.PHYTOCHEM.2006.03.013>
- Zulfajri, M., & Muttakin. (2018). Activity analysis of anthocyanin from *Syzygium cumini* (L.) skeels as a natural indicator in acid-base titration. *Rasayan J. Chem* 11(1): 135–141. <https://doi.org/10.7324/RJC.2018.1111983>