

# WOOD IN MY WEBSITE: A CASE REPORT

**Ahmad Muslim MY<sup>1</sup> and Gunasagaran J<sup>1</sup>.**

<sup>1</sup>National Orthopaedic Centre of Excellence for Research and Learning (NOCERAL), Department of Orthopaedic Surgery, Faculty of Medicine, University of Malaya, 50603 Kuala Lumpur, Malaysia

## Correspondence:

Jayaletchumi Gunasagaran,  
National Orthopaedic Centre of Excellence in Research and Learning (NOCERAL),  
Department of Orthopaedic Surgery,  
Faculty of Medicine, University of Malaya,  
50603 Kuala Lumpur, Malaysia  
Email: jayaletchumi@um.edu.my

## Abstract

Penetrating injuries to the hand are common occurrences in the casualty. Careless removal of the penetrating foreign body potentially leads to retained fragments and subsequently infection. In diabetic patients, the presentation might be delayed due to poor immune response and peripheral neuropathy; leading to complications such as spread of infection and amputation. Detecting retained radiolucent foreign body when the entry wound had healed may pose a challenge. We present a case of retained pieces of wood in the first webspace of the hand which presents with infection distant from the healed entry site.

**Keywords:** Case reports, Foreign bodies, Wood, Wounds

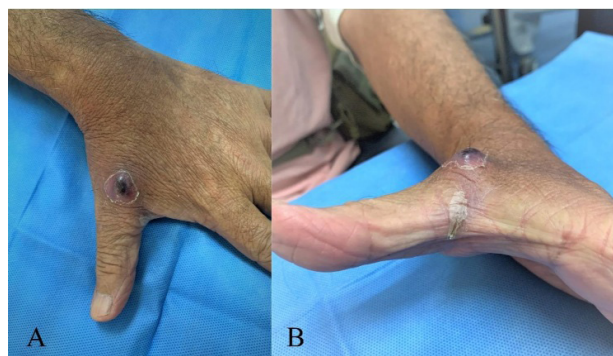
## Introduction

Retained foreign body can be disastrous especially in diabetic patients. Usually, these are small radiolucent bodies which are undetectable upon physical examination and radiographic imaging. Larger foreign bodies are often apparent clinically especially when there is an entry wound while radiopaque bodies are detectable in plain radiographs. We report a case of retained sizeable wood pieces in the hand of a diabetic patient with abscess away from the healed entry wound.

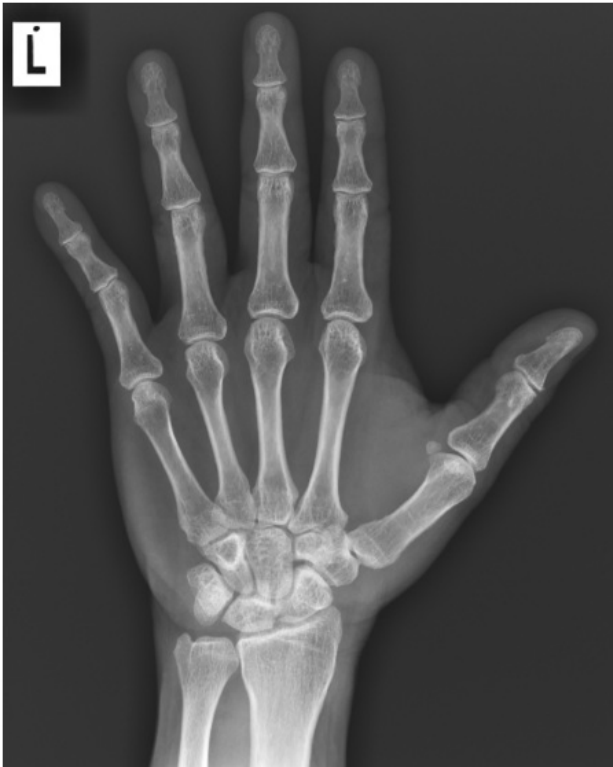## Case Report

A 65-year-old gentleman with diabetes mellitus was gardening when he fell on his outstretched left hand. The hand landed on pieces of wood on the ground which punctured his first webspace at distal margin. He removed all the visualised wood pieces, irrigated the wound and dressed it with antiseptic solution. The following day, he noted swelling at the left hand and visited a local clinic. The wound was apparently clean, and he was discharged with Cloxacillin tablets and analgesia. Subsequently, the swelling reduced and the wound healed within 5 days. Despite that, there was still mild pain localised at the dorsum of the first webspace distant from the wound. A swelling later developed at this area; when he presented

to the casualty a week after the injury. Otherwise, there was neither fever nor loss of function. Clinically, there was a 2 x 2 cm erythematous swelling over the dorsal aspect of the first webspace which was minimally tender (Figure 1A). There was a healed wound noted at the first webspace (Figure 1B). Plain radiograph did not reveal any radiopaque foreign body (Figure 2). White cell count was within normal range. As there was little sign of acute infection, the patient was given an appointment in a week for ultrasound scan.

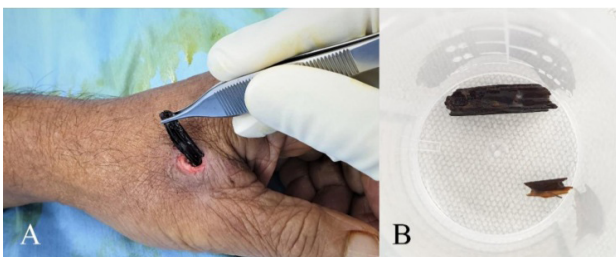


**Figure 1:** (A) The erythematous swelling at presentation; distant from the healed puncture wound, (B) Completely healed puncture wound at the 1<sup>st</sup> webspace



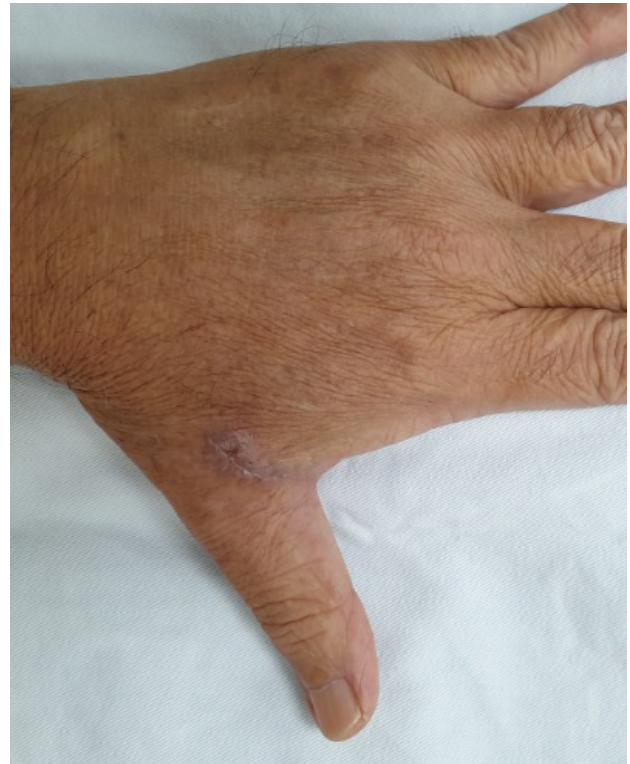**Figure 2:** Plain radiograph showing increased soft tissue density at the first web space with no obvious foreign body visible

However, the patient returned to the casualty 2 days later as the swelling had ruptured. There was minimal seropurulent discharge from the ruptured swelling. He was admitted for debridement and exploration. Intraoperatively, two pieces of wood measuring 2.5 x 0.6 x 0.3 cm and 0.5 x 0.3 x 0.2 cm were found within the subcutaneous layer of the dorsum of the first web space just beneath the skin and they were extracted (Figure 3A, 3B). The surrounding subcutaneous tissues were unhealthy. The foreign body tract was in the direction of the healed entry wound and the tract was curetted. The healed entry wound skin was left intact. Tissue sample was sent for culture after which intravenous ampicillin-sulbactam was started.



**Figure 3:** (A) Extraction of the foreign body. Note the size of the foreign body in relation to the web space, (B) The pieces of wood extracted; measuring 2.5 x 0.6 x 0.3 cm and 0.5 x 0.3 x 0.2 cm respectively

The wound was dressed daily, and the patient was discharged on the second day after surgery with oral ampicillin-sulbactam. Follow up review, 3 days later showed a clean wound. Hence, delayed primary closure was performed. Tissue culture grew methicillin-susceptible *Staphylococcus aureus*. Antibiotic was stopped after a 7-day course. On follow up visit, 2 weeks later, the wound had healed (Figure 4) and there was full range of motion of the thumb. The patient was grateful and relieved that his condition had resolved rather quickly.



**Figure 4:** Surgical wound healed at two weeks follow up

**Discussion**

The size of the foreign body extracted from the web space took us by surprise. Especially with the small entry wound which had completely healed. As stated by Anderson et al. (1982), “No wound is too small to harbour a large foreign body” (1). Dumarey et al. (2004) reported a similar case with a bigger wood piece measuring 3.0 x 1.0 x 0.2 cm retained in the thenar region for 6 weeks (2). Likewise, Dumarey’s patient also had no fever and no loss of function. On the other hand, other authors found wood to be extremely inflammatory (3). Yanay et al. (2001) reported severe necrotising fasciitis of the lower limb in an 8-year-old child following retained wooden foreign body, requiring multiple surgeries including hip disarticulation (4). Thus, missed diagnoses can be disastrous. The medical officers, who review patients at initial presentations, should suspect retained foreign body despite history of complete removal by confident patients.

Infection in a diabetic patient's hand is of great concern to hand surgeons due to the anticipated complications. Following debridement, higher rate of complications including persistent infection requiring further surgical intervention, amputation, stiffness and arthrodesis are seen. In comparison to non-diabetic patients, complication rates can be higher in diabetic patients by about 6-folds. This is attributed to the compromised state of immune system, delayed presentation due to peripheral neuropathy and masked clinical picture, and vascular disease resulting in delayed wound healing (5). Therefore, prompt accurate diagnosis is crucial as early surgical intervention may reduce the morbidity.

In our patient, although elderly and diabetic, the healing was fortunately uncomplicated despite the late presentation. The fact that the entry wound was able to heal spontaneously within a short duration ensured us of good healing potential in him. We believe that a good diabetic control is paramount for wound healing and eradication of infection. Although our patient's HbA1c level was 7.3% which was higher than the recommended target of  $\leq 6.5\%$ , his capillary blood glucose throughout the hospital stay was within normal range.

Wood is only visualised in 15% of plain radiograph studies. Nonetheless, secondary changes such as lytic bone lesions, periosteal reaction and pseudotumor of the soft tissue had been reported to be visible in retained wooded foreign bodies (1). These, however, can only be seen after some time. Due to the frequency of retained fragments, Dumarey et al. (2) recommended ultrasound scan should be done in any case of penetrating injury by foreign bodies given the high sensitivity. The use of intraoperative ultrasound may help to detect small fragments not visualised during debridement (2). In our case, the foreign body could have been detected earlier if ultrasound was done during his first clinic visit. Hence, the consideration of ultrasound machines availability in clinics and casualty units for prompt investigation and management may improve patient care for similar patients.

### **Conclusion**

Penetrating injuries should be dealt with meticulously, especially in diabetic population. When the penetrating foreign body is clinically undetectable and radiolucent, ultrasound should be done to rule out any retained fragments. Areas distant from the entry site should also be carefully examined for possible retained foreign body. Despite higher complication rates in diabetic patients following hand infections, uncomplicated healing is achievable with proper debridement and good glucose control.

### **References**

1. Anderson MA, Newmeyer WL, Kilgore ES. Diagnosis and treatment of retained foreign bodies in the hand. *Am J Surg.* 1982;144(1):63–7.

2. Dumarey A, De Maeseneer M, Ernst C. Large wooden foreign body in the hand: Recognition of occult fragments with ultrasound. *Emerg Radiol.* 2004;10(6):337–9.
3. Graham DD. Ultrasound in the emergency department: Detection of wooden foreign bodies in the soft tissues. *J Emerg Med.* 2002;22(1):75–9.
4. Yanay O, Vaughan DJ, Diab M, Brownstein D, Brogan T V. Retained wooden foreign body in a child's thigh complicated by severe necrotizing fasciitis: A case report and discussion of imaging modalities for early diagnosis. *Pediatr Emerg Care.* 2001;17(5):354–5.
5. Schmidt G, Piponov H, Chuang D, Gonzalez M. Hand infections in the immunocompromised patient: An update. *J Hand Surg Am.* 2019;44(2):144–9.