

HYPERFINE DESCRIPTION OF HUMAN CREATION IN THE THREE DARK ZONES IN QURAN[○]

Gamal H. E. Hassanein¹

ABSTRACT

Most commentators interpreted the three dark zones mentioned in Surah Az-Zumar, 39, Ayah 6 of the noble Quran as; the darkness of the abdomen, the darkness of the uterus and the darkness of the placenta. According to contemporary embryology, this interpretation would be a matter of debate. The aim of the current study was to put an acceptable scientific interpretation of these zones which document their hyperfine description in holy Quran. The present study, based upon other verses revealed in Quran, postulated that the appropriate interpretation of these zones , from outside to inside , would be the cavity of the uterus, the cavity of the chorionic vesicle and the amniotic cavity. The harmful effect of exposing early embryonic stages to light would explain the importance of darkness in these zones. In addition, the three zones disappear during the 18th to 20th weeks (5th month) of pregnancy due to fusion of membranes separating these zones. At this time, embryo is only growing after finishing the developmental stages. *In conclusion:* This article finds that Quran was hyperfine in describing that creation passes through stages which are proceeding in three dark zones. The three zones are only existing during progress of embryonic stages and disappear after their completion.

Keywords: *Dark zones, dark veils, Surah Az-Zumar, human creation, The Quran, embryo.*

[○] This article was submitted on: 03/08/2015 and accepted for publication on: 04/11/2015.

¹Anatomy Department, Faculty of Medicine, Zagazig University, Egypt, email: gamalhs@hotmail.com

1.0 INTRODUCTION

The Quran states that our creation passes through stages within three dark zones. Allah, the Almighty, Said in *Surah Al-Zumar*, 39, Ayah 6:

"يَخْلُقُكُمْ فِي بُطُونِ أُمَّهَاتِكُمْ خَلْقًا مِّنْ بَعْدِ خَلْقٍ فِي ظُلُمَاتٍ ثَلَاثٍ" (الزمر , ٣٩ : آية ٦)

“He (God) makes you in the wombs of your mothers; in stages , one after another , in three veils of darkness”

The general interpretation of these dark zones in standard commentaries (*Ibn Kathir*, *al-Tabari*, *al-Suyuti*, *ibn ‘Ashur*) was ; the darkness of the abdomen, the darkness of the uterus and the darkness of the placenta

In the early eighties, an anatomical explanation to these dark zones was; the abdominal wall, the uterus, and the amniochorionic membrane (Moore, 1982). However, the aforementioned interpretation of these three dark zones would be a matter of debate being incompatible with facts described in textbooks of contemporary embryology (Sadler, 2012; Carlson, 2014). In addition, the harmful effect of exposing early embryonic stages to light (Denial, 1964; Hirao & Yanagimachi, 1978; Schumacher & Fischer, 1988), would explain the importance of darkness in these zones. The aim of the current study was to postulate an interpretation of these zones which is not only in accordance with scientific data, but also document their hyperfine description in noble Quran.

2.0 REVIEW OF PREVIOUS COMMENTARIES (TAFASIR)

Surah Az-Zumar is a Makki Surah (revealed in the city of Makkah) and its *sixth ayah* (verse 6) is reporting that human embryo develops in stages, one after the other, within three zones of darkness. General commentaries (tafasir) as Ibn Kathir, Al-Tabari, Al- Qurtubi and Al- Jalalayn interpreted these three dark veils or zones as “darkness of the abdomen, darkness of the uterus and darkness of the placenta”. Ibn Ashour similarly gave the same interpretation, however, he described that “placenta is a membrane of skin created simultaneously with the embryo and surround him for his protection. It enables embryo to achieve his independence from the mother through the nutrients that are brought in the own blood circulation of him. In the mention of these dark zones, an alert to the extended knowledge of Allah, the Almighty, about things and His power to reach them in their most degree of secret (hidden)”

Concerning creation in stages, one after another, that takes place within these three zones of darkness, Ibn Kathir described that: “each of you is first a *nutfah*, then it develops into an *alaqah* , then into a *mudghah* and then

he is created and became formed of bones, flesh, nerves and veins. Then, the soul is blown into him and he changes into another creation". Al- Jalalayn described these stages to be "the *nutafa* , *alaqa* and *mudagh*" . On the other hand, At-Tabari said that "He (God) makes within a *nutfah* then changes it to an *alaqah* then to a *mughah* , then to *izam* (bones) , then *yakso al- izam lahm* (clothe the bones with flesh) , then *youn-sheea'aho khalkan akher* (develops it into an another creation)". Al-Qurtubi ^[4] described the stages of creation to be "*nutfah* , then *alaqah* , then *mudghah* , then *izam* (bones) , then *lahm* (flesh)."

Muslim scholars described that Qur'an divided the embryonic development into the following consecutive stages: "*nutfah*" which is in the Arabic language means a little water or a drop of fluid. The "*nutfah amshaj*" which in the Arabic language consists of two words: the noun "*nutfah*" in the singular form and the adjective "*amshaj*" which is a plural form used to indicate mixing of more than two things. Thus "*nutfah amshaj*" could indicate a "*nutfah*" formed of union between male and female gametes and it corresponds to the zygote in modern embryology. The "*nutfah*" is followed by "*alaqah*" which clings to the lining of the uterus, followed by "*mudghah*" which is a little lump of flesh. Then, "*mudghah*" converts into "*izam*" (bone formation) followed by "*kissat bel lahm*" (clothing of bones with flesh) and finally "*nasha'a okhrah*" " (development into another creation) (Moore et al. 1987).

Linguistic Review

The word dark (in Arabic *zolmah*) was explained in Arabic dictionaries (Ibn Faris n.d; Ibn Manzur, n.d, al-firuzabadi, n.d) to mean the opposite state to light or the disappearance of light. According to these dictionaries, the single form of the word is called *zolmah*, but the word has multiple plural forms; one of them is *zolomat* (which is the one used in the , Ayah 6 of Surah Az-Zumar, 39). Thus, it could be appreciated that the word *zolmah* (dark) is used to describe the state of illumination of a certain place and denotes that the light in that place had gone. The use of the word in the plural form *zolomat* indicates that there are more than one dark zone. Therefore, *Quran* used the plural form '*zolomat*' to describe that the embryo passes from a creation stage to another indicating that there are three different dark zones around the embryo.

3.0 SCIENTIFIC REVIEW

A-The mother:

The wall of the uterus consists of three layers: (a) endometrium or mucosa lining the inside wall; myometrium, a thick layer of smooth muscle; and perimetrium, the peritoneal covering lining the outside wall ^[8]. The term

decidua (L. *deciduus*, a falling off) is applied to the gravid endometrium (the functional layer of the endometrium in a pregnant woman). The name indicates that this part of the endometrium separates (falls away) from the uterus at parturition (childbirth). Three regions of the decidua are named according to their relation to the implantation site. The part deep to the conceptus which forms the maternal component of the placenta is called the decidua basalis; the superficial portion overlying the conceptus is known as the decidua capsularis; and all the remaining endometrium is referred to as the decidua parietalis (*vera*) (Moore et. al., 2000). The decidua capsularis atrophies, presumably because it does not get any blood supply. The trophoblastic villi of this part degenerate and form the chorion leave, while proliferating villi at the decidua basalis give rise to the chorion frondosum, the site of the future placenta (Kruger&Botha, 2007). With further growth of the embryo, the decidua capsularis is stretched and thinned, and comes into contact with the decidua parietalis on the opposite wall of the uterus (Rana, 1998).

B- The embryo

During the first steps of implantation, an enlarged intercellular space between embryoblast and neighboring trophoblastic cells can be observed. Some small cells that line the inner surface of the trophoblast in this particular region have been named the amniogenic cells. They are the forerunner of the amniotic epithelium; the cleft separating them from the embryoblast is the early amniotic cavity. Because of its continuous expansion, the amniotic cavity slowly surrounds the embryo from all sides and finally covers the umbilical cord (Benirschke&Kaufmann, 2000). On day 8, cells on the periphery of the newly formed hypoblast begin to migrate out over the inner surface of the cytotrophoblast, becoming flattened and squamous. By day 12, these cells form a thin membrane of extraembryonic endoderm completely lining the former blastocyst cavity.

This membrane is called the exocoelomic membrane or Heuser's membrane, and the former blastocyst cavity is now called the primary yolk sac or exocoelomic cavity (Larsen, 1993). The extraembryonic mesoderm develops from the epiblast and consists of loosely arranged cells that fill the space between the exocoelomic membrane and the cytotrophoblast. Large spaces develop in the extraembryonic mesoderm and coalesce to form the extraembryonic coelom. The extraembryonic coelom divides the extraembryonic mesoderm into the extraembryonic somatic mesoderm and extraembryonic visceral mesoderm. The extraembryonic somatic mesoderm lines the trophoblast, forms the connecting stalk, and covers the amnion. The

extraembryonic visceral mesoderm covers the yolk sac. As soon as the extraembryonic somatic mesoderm and the extraembryonic visceral mesoderm form, one can delineate the chorion, which consists of the extraembryonic somatic mesoderm, cytotrophoblast, and syncytiotrophoblast. As the chorion is delineated, the extraembryonic coelom is now called the chorionic cavity. The conceptus is suspended by the connecting stalk within the chorionic cavity (Dudek&Fix, 2005).

C – The relationship between decidua, amnion and chorion

Although the amniotic cavity is at first smaller than the blastocyst cavity, it expands steadily; by the eighth week the amnion encloses the entire embryo ^[21]. Fusion of amnion and chorion completes around the 12th week of development. Before that time, the amnion forms a separate bubble within the chorionic sac; it is surrounded and separated from the chorion by chorionic fluid, the magma reticulare, a viscous and thixotropic gel within which some stellate cells are dispersed ^[22] The chorioamnion, in turn, fuses with the decidua capsularis. By about 18-20 weeks of gestation, progressive enlargement of the fetal sac results in obliteration of the uterine cavity as the decidua capsularis fuses with the decidua parietalis of the opposite uterine wall. At 20th weeks of gestation, the dome of the uterus is typically palpable at the level of the maternal umbilicus; thereafter, uterine size, as measured by fundal height above the umbilicus, increases by about 1 cm/gestational week (Faye-Petersen et al., 2006).

D- Embryonic growth

By the end of the second week of post-fertilization development, the pre embryo has formed as a flattened disc consisting of three germ layers; ectoderm, mesoderm and endoderm (Jones&Lopez, 2006). The embryonic period occurs from the third to the eighth week after conception. During this short time, every major organ takes shape, in at least a primitive form, in a process called organogenesis (Sigelman&Rider, 2009). The embryonic period ends in the 10th week of pregnancy (stage 23; 8th postovulatory week). During the fetal period, growth of the embryo and maturation of the organ systems take place. In the first half of the fetal period (up to the 20th week of pregnancy), the embryo grows mainly in length, whereas toward the end of pregnancy it gains weight (Drews, 1995).

E- Importance of darkness for embryogenesis

Denial observed that visible light caused an inhibition of cleavage of rabbit embryos (Denial, 1964). Moreover, the short-wavelength visible light (less than 480 nm) emitted from ordinary sources was detrimental to hamster oocytes; it disturbed the completion of meiosis in fertilized hamster oocytes (Hirao&yanagimachi, 1978). On the other hand, Schumacher and Fischer observed that exposure of early cleavage-stage rabbit embryos (2-cell stages) to standard room light significantly impaired cell proliferation (Schumacher&Fischer, 1988). Hegele-Hartung et al (1988) studied by light and electron microscopy as well as by the cytochemical demonstration of glycogen, the effects of visible (standard) lighting (1600 lux) and room (standard) temperature (23 degrees C) on early cleavage stage embryos (day 1 p.c.) and morulae (day 3 p.c.) of rabbits during a 24 h in-vitro culture compared to control embryos cultured in darkness at 37 degrees C. The results demonstrate that day 1 embryos were clearly more susceptible to lighting whereas day 3 embryos were more affected by temperature.

The mode of damage exerted by both the physical environmental factors was different. Reduction to standard temperature interfered mainly with the organization of the cytoskeleton and intracellular transport of organelles, while exposure to standard lighting led to cell degeneration and death. Hegele-Hartung et al. (1991) in a time course study (4-20 h) rabbit early cleavage stages (day 1 p.c.) and compacted morulae (day 3 p.c.) were exposed to visible light or room temperature (23 degrees C), respectively. An 8 h light exposure of day 1 embryos caused alterations in nuclear morphology (lobulated nuclei, loss of nucleolar differentiation), an increased electron density of the cytoplasm, and cellular fragmentation leading to a considerable degeneration of blastomeres (central clustering of organelles, loss of cell surface differentiation) after a 20 h exposure. Umaoka et al (1992) reported that the developmental rates of 1-cell embryos to the 4- and 8-cell stages of hamster embryos collected and cultured under dark conditions (70 lux) were significantly higher than those under light conditions (1600 lux). Light irradiation during the culture of 1-cell embryos suppressed subsequent development. Light irradiation of 30 minutes or more completely blocked development to the 2-cell stage. When 1-cell embryos were irradiated through a yellow filter, cutting the light wavelengths to less than 500 nm, embryonic development was still suppressed. Inhibitory effects of light irradiation on the development of 2- and 8-cell embryos were also observed. The early-stage embryos were sensitive to light exposure; however, severe light exposure adversely affects the development of embryos at any stage. Thus, the

protection of embryos from light exposure at all stages of embryo manipulation, from collection to culture, is essential.

Although , Bedford and Dobrenis (1989) and Barlow et al. (1992) described absence of significant effects of visible light on oocytes of rabbit and mouse respectively , yet Ottosen et al. (2007) reported that exposure to visible light (400–700 nm wavelengths) is an unnatural stress factor to preimplantation embryos cultured *in vitro*. Ambient light, in contrast, was not a significant contributor to light stress and the use of dark laboratories is not justified.

4.0 SUMMARY AND CONCLUSION

The Quran states that our creation passes through stages within three dark zones. Allah, the Almighty, Said in *Surah Az-Zumar, 39, Ayah 6*:

"يَخْلُقُكُمْ فِي بُطُونِ أُمَّهَاتِكُمْ خَلْقًا مِّنْ بَعْدِ خَلْقٍ فِي ظُلُمَاتٍ ثَلَاثٍ" (الزمر: ٣٩).

"He (God) makes you in the wombs of your mothers; in stages , one after another , in three veils of darkness"

Most commentators interpreted these three dark zones as; the darkness of the abdomen, the darkness of the uterus and the darkness of the placenta. According to contemporary embryology, this interpretation would be a matter of debate. The aforementioned interpretation of these three dark zones is criticized in two aspects ; first : the placenta is not a sac , being only facing one side of the embryo , so it could not be one of the three zones surrounding the embryo , second : considering the abdomen or abdominal wall one of these zones is inaccurate. Our creation in the abdomen of our mothers, as stated in *Surah Az-Zumar, Ayah 6*, occurs in the three veils or zones. This indicates that the abdomen could not be one of these three zones. The support to this view was stated in the Quran itself; Allah, the Almighty, Said in *Surah Ala-i-mran, 3, Ayah 6*:

"هُوَ الَّذِي يُصَوِّرُكُمْ فِي الْأَرْحَامِ كَيْفَ يَشَاءُ لَآ إِلَهَ إِلَّا هُوَ الْعَزِيزُ الْحَكِيمُ" (آل عمران: ٦).

"He it is Who shapes you in the wombs as He likes ; there is no god but He, the Exalted in Might, the Wise"

According to the aforementioned ayah, the place of creation is the uterus and its cavity would be the first of these three dark zones. Moreover, Allah, the Almighty, Said in *Surah Al-Mu'minun, 23, Ayah 13*:

"ثُمَّ جَعَلْنَا نُطْفَةَ فِي قَرَارٍ مَّكِينٍ" (المؤمنون: ١٣).

“Then We placed him as (a drop of) sperm in a place of rest, firmly fixed ”

The place of rest, firmly fixed described in the previous ayah , which receives the *nutfah* , is the uterus. This is another evidence that the cavity of uterus must be the first of the three dark zones described in ayah 6 of Surah Az-Zumar.

Standard textbook of contemporary embryology described that the cavity of gravid uterus contains two sacs around the embryo; the amniotic cavity and the chorionic cavity (Diagram 1). Thus, the three dark zones around the embryo; from outside within are: the cavity of the uterus, the cavity of the chorionic vesicle and the amniotic cavity.

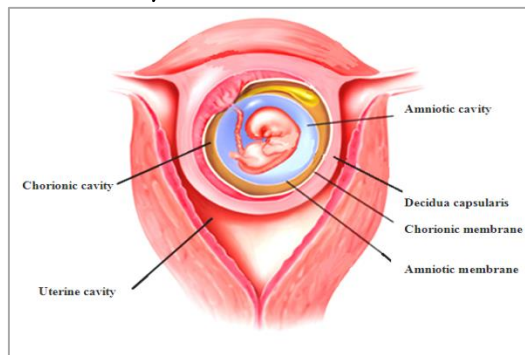


Diagram 1: A coronal section in a gravid uterus showing the three zones around the embryo; amniotic cavity, chorionic cavity and uterine cavity with their separating membranes; amniotic membrane, chorionic membrane and decidua.

The amniotic cavity is enclosing the entire embryo by the 8th week and the fusion of amniotic and chorionic cavities, through contact between the amniotic membrane and chorionic membrane is completed around the 12th week of development. Then, the chorioamniotic membrane, in turn, fuses with the decidua capsularis. By about 18-20 weeks of gestation, progressive enlargement of the fetal sac results in obliteration of the uterine cavity as the decidua capsularis fuses with the decidua parietalis of the opposite uterine wall. Therefore, the three zones begin to join at the 8th week and end about 18th to 20th weeks, at this time at that time, organogenesis of the embryo had finished and it is only continuing its growth.

These zones are dark, due to the inability of light to penetrate through the body of the mother, although the membranes separating them from each other allow light to pass through them. Darkness is an essential requirement for

the normal development of the embryo and many scientific studies had proved that the exposure of the early embryonic stages to light causes a negative effect, particularly on the early embryonic stages.

In conclusion, this article finds that Quran was hyperfine in describing that creation passes through stages which are proceeding in three dark zones as revealed in ayah 6 of Surah Az-Zumar. The current study postulated that the appropriate interpretation of these zones, from outside to inside, would be the cavity of the uterus, the cavity of the chorionic vesicle and the amniotic cavity. The harmful effect of exposing early embryonic stages to light would explain the importance of darkness in these zones. In addition, the three zones are only existing during progress of embryonic stages and disappear during the 18th to 20th weeks (5th month) of pregnancy due to fusion of membranes separating these zones. At this time, embryo is only growing after finishing the developmental stages.

5.0 REFERENCES

- Barlow, P., Puissant, F., van der Zwalm, P., Vandromme, J., Trigaux, P., Leroy, F. (1992). In vitro fertilization, development and implantation after exposure of mature mouse oocytes to visible light. *Mol Reprod Dev*, 33, pp. 297-302.
- Bedford, J. M. & Dobrenis, A. (1989). Light exposure of oocytes and pregnancy rates after their transfer in the rabbit. *J. Reprod. Fert* 85, pp. 477 – 481
- Benirschke, K. & Kaufmann, P. (2000). Anatomy and pathology of the placental membranes. In: *Pathology of the human placenta*. Springer, 4th edn.
- Carlson, B. M. (2014). *Human Embryology and Developmental biology*. Elsevier / Saunders, 5th edn.
- Denial, J. C. (1964). Cleavage of mammalian ova inhibited by visible light. *Nature Lond*, 201, pp. 316-317.
- Drews, U. (1995). Fetal period. In: *Color atlas of embryology*. Georg Thieme Verlag.
- Dudek, R. W & Fix, J. D. (2005). Week 2 of human development. In: *Embryology*. Lippincott Williams & Wilkins, 5th edn.
- Faye-Petersen, O. M., Heller, D. S and Joshi, V. V. (2006). Development of the placenta. In: *Handbook of placental pathology*. Taylor & Francis Group, 2nd edn.

- Hegele-Hartung, C., Schumacher, A., Fischer, B. (1988). Ultrastructure of preimplantation rabbit embryos exposed to visible light and room temperature. *Anat Embryol (Berl)*, 178 (3), pp. 229-41
- Hegele-Hartung, C., Schumacher, A., Fischer, B. (1991). Effects of visible light and room temperature on the ultrastructure of preimplantation rabbit embryos: a time course study. *Anat Embryol (Berl)*, 183(6), pp. 559-71.
- Hirao, Y. & Yanagimachi, R. (1978). Detrimental effect of visible light on meiosis of mammalian eggs in vitro. *J Exp Zool*, 206, pp. 365-369.
- Jones, R. E&López, K.H. (2006). Embryonic and fetal development. In: *Human reproductive biology*. Academic Press, 3rd edn.
- Kruger, T. F. & Botha, M. H. (2007). Development of fetal membranes In: *Clinical Gynaecology*. Juta &Co.Ltd, 3rd edn.
- Larsen, W.J. (1993). The second week. In: *human embryology Churchill Livingstone*.
- Moore, K L. & al-Zindani, A. (1982). The Developing Human with Islamic Additions. Philadelphia: W.B. Saunders Company, 3rd edn.
- Moore, K. L, Johnson, E. M, Persaud. T.V.N, Goeringer. G.C, Zindani A. M, and Ahmed, M. A. (1987). Human development as described in Qura'n and Sunnah: correlation with modern embryology. The First International Conference on Scientific Signs of the Qur'an and Sunnah, Islamabad, Pakistan.
- Moore, K. L., Persaud, T. V. N. and Shiota, K. (2000). Color Atlas of Clinical Embryology. Philadelphia, PA: W.B. Saunders, 2nd edn.
- Ottosen, L. D., Hindkjaer, J., Ingerslev, J. (2007). Light exposure of the ovum and preimplantation embryo during ART procedures. *J Assist Reprod Genet*, 24, 99-103.
- Rana, M. W. (1998). Placentaion, in *Human embryology made easy*. Harwood academic publishers.
- Sadler, T. W. (2012). Langman's Medical Embryology. Lippincott Williams & Wilkins, 12th edn.
- Schumacher, A. & Fischer, B. (1988). Influence of visible light and room temperature on cell proliferation in preimplantation rabbit embryos. *J Reprod Fertil*, 84, pp. 197-204
- Sigelman, C.K, & Rider, E. A. (2009). Prenatal development and birth. In: *Life-span Human development*. Wadsworth, Cengage Learning, 6th edn.
- Umaoka, Y., Noda, Y., Nakayama, T., Narimoto, K., Mori, T. (1992). Effect of visual light *in vitro* on embryonic development in the hamster. *Theriogenology*, 38, pp. 1045-54.